Abdominal Radiography

Jason Arble, DVM, MS, DACVR
Assistant Professor, Radiology
Center for Veterinary Health Sciences
Oklahoma State University

Technique

- ⬇ kVp = ⬆ contrast (⬆ mAs)
- Use grid if ≥ 10 cm thick
- VD and lateral views
- Cranial diaphragm to coxofemoral joints
  - Often requires separate films for large dogs
    - Often different technique cranial vs. caudal (~10%)
- Peak expiration
  - Decrease motion
  - Decrease organ compression

Technique

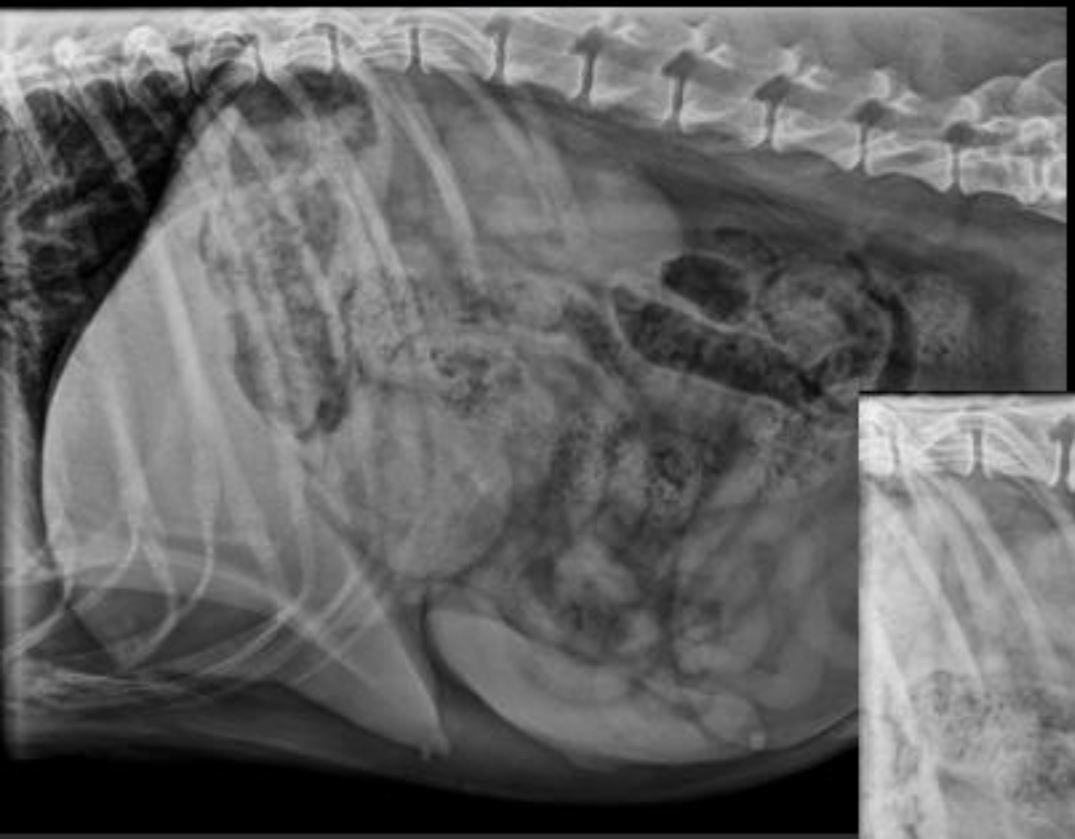

Interpretation

- Roentgen signs
  - Size
  - Number
  - Shape
  - Position
  - Opacity
  - Margination

Interpretation: Anatomy

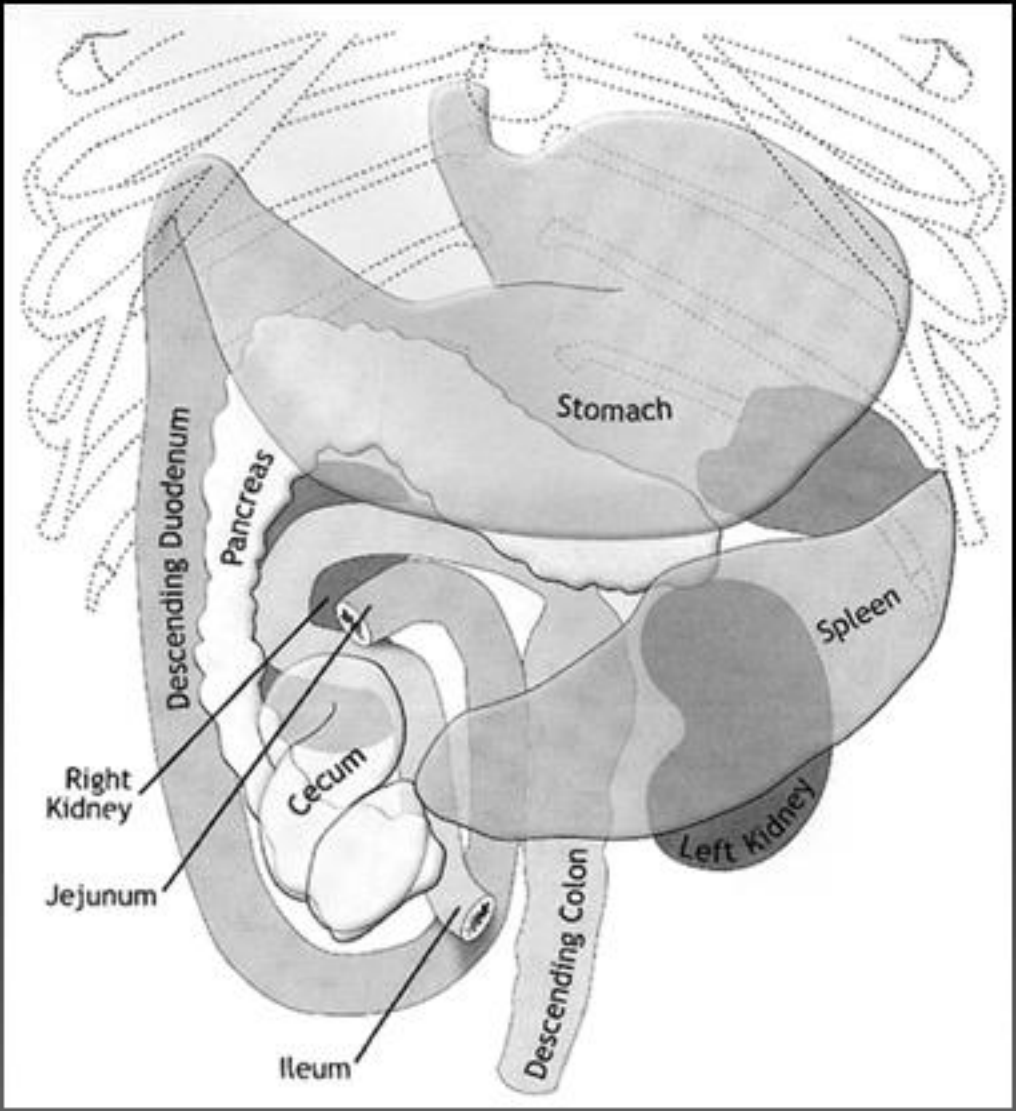

Serosal Detail

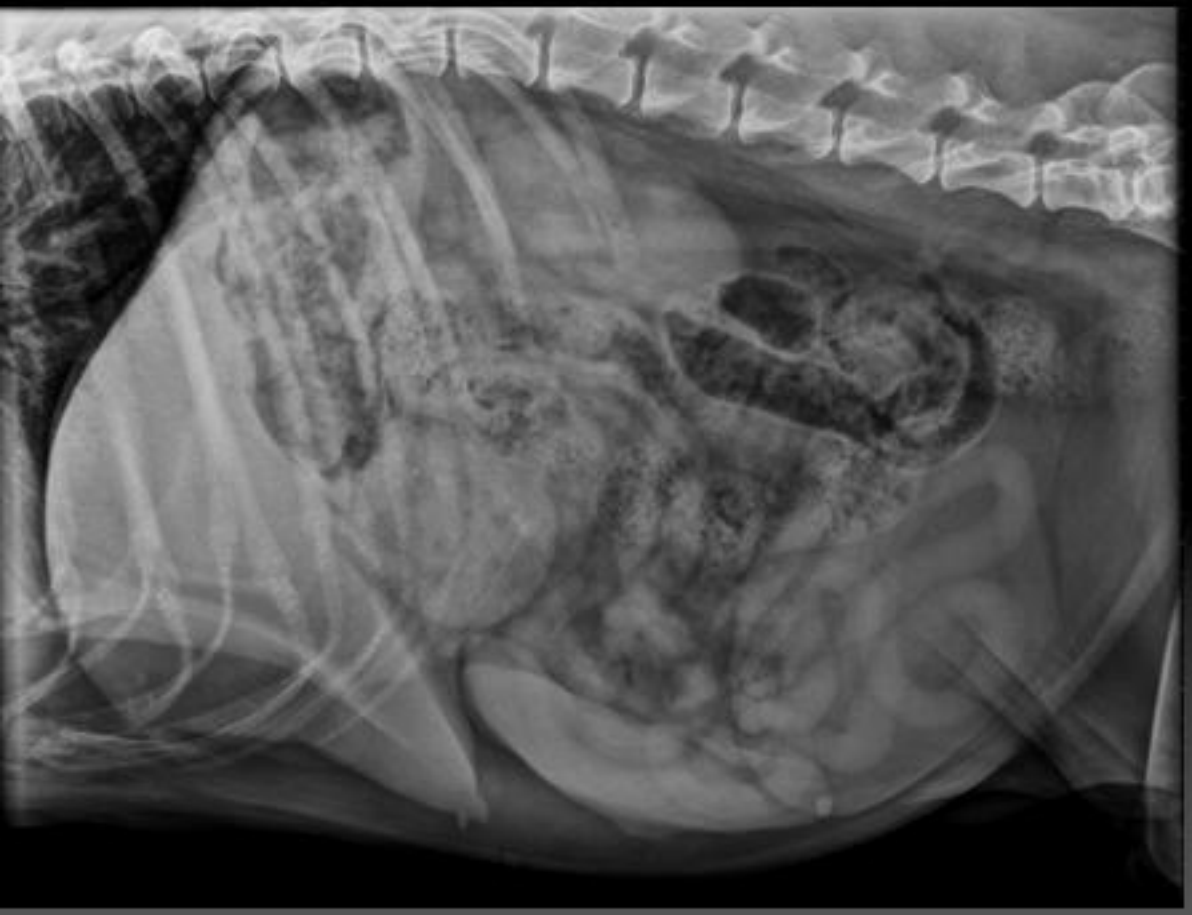

- Fat is responsible for abdominal serosal detail

Serosal Detail

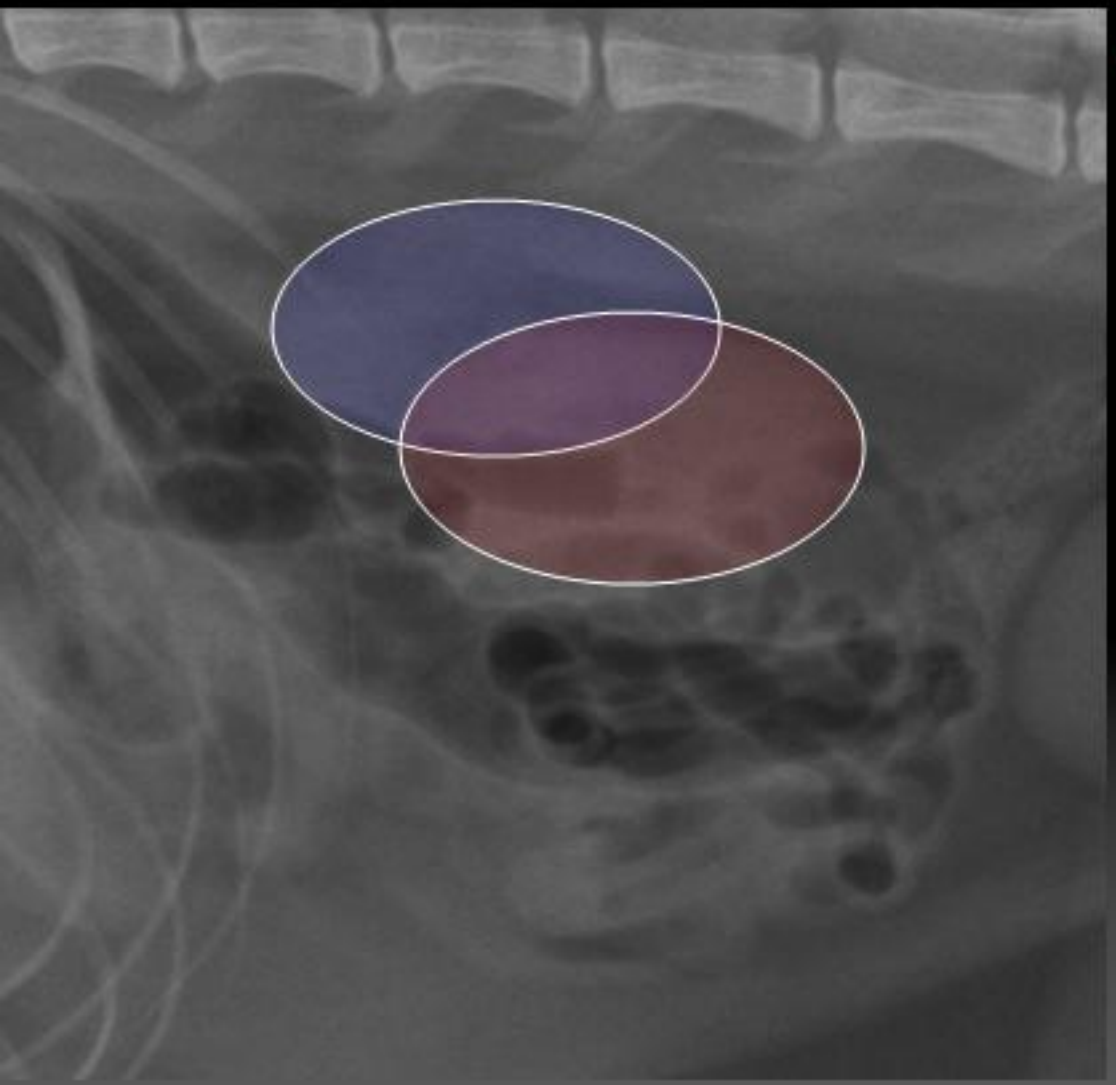

- **SUMMATION**
  - Superimposition of 2 parts not in contact

Serosal Detail

- Effusion/Ascites

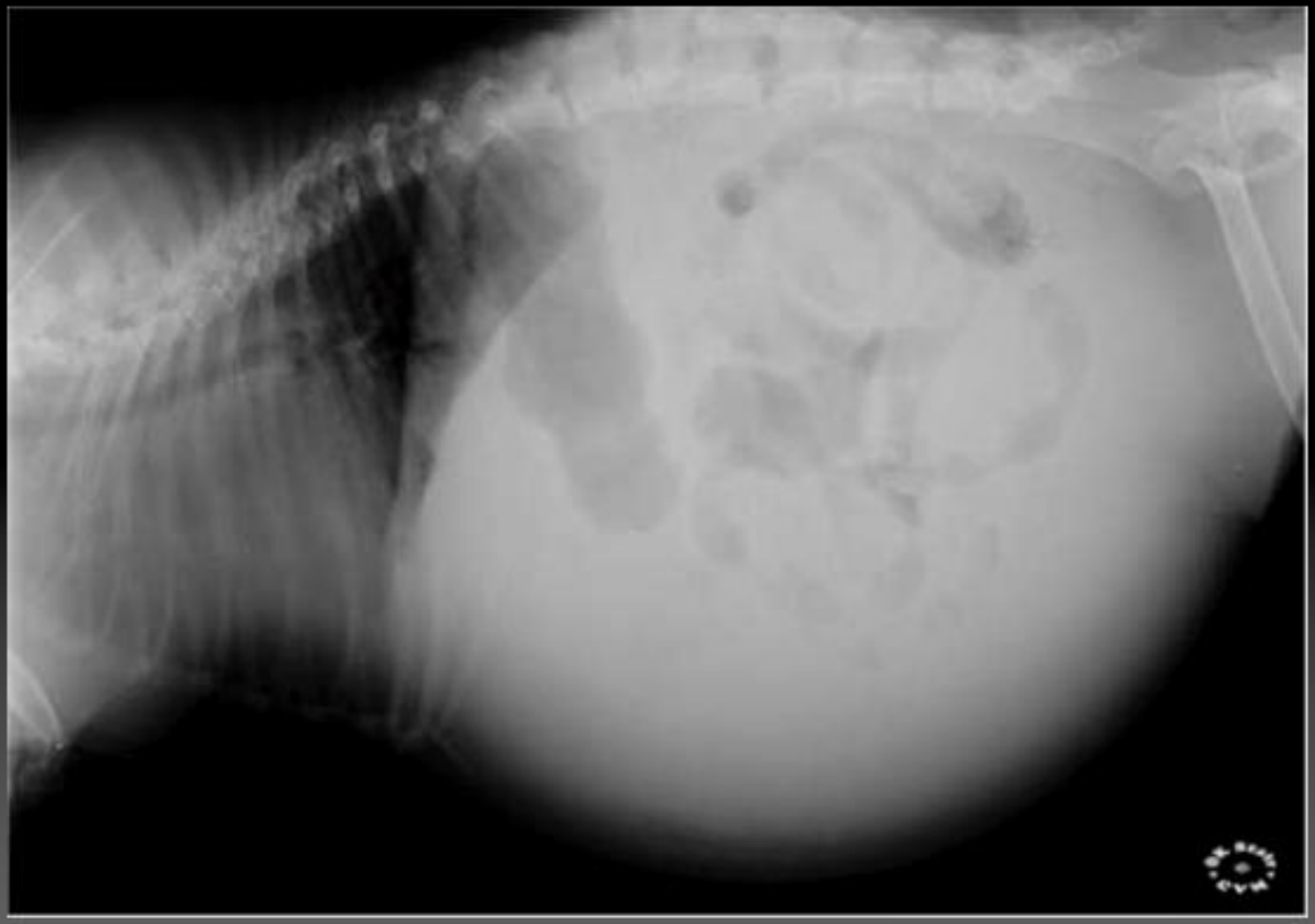

Effusion

- Peritoneal Space
  - Stomach, liver, intestines, urinary bladder, prostate/uterus, etc…
- Retroperitoneal Space
  - Kidneys, adrenal glands, , sublumbar lnn, etc…

Effusion- Peritoneal

Effusion- Retroperitoneal

Serosal Detail

- **SILHOUETTE**
  - Border effacement
  - 2 structures of the same opacity touching

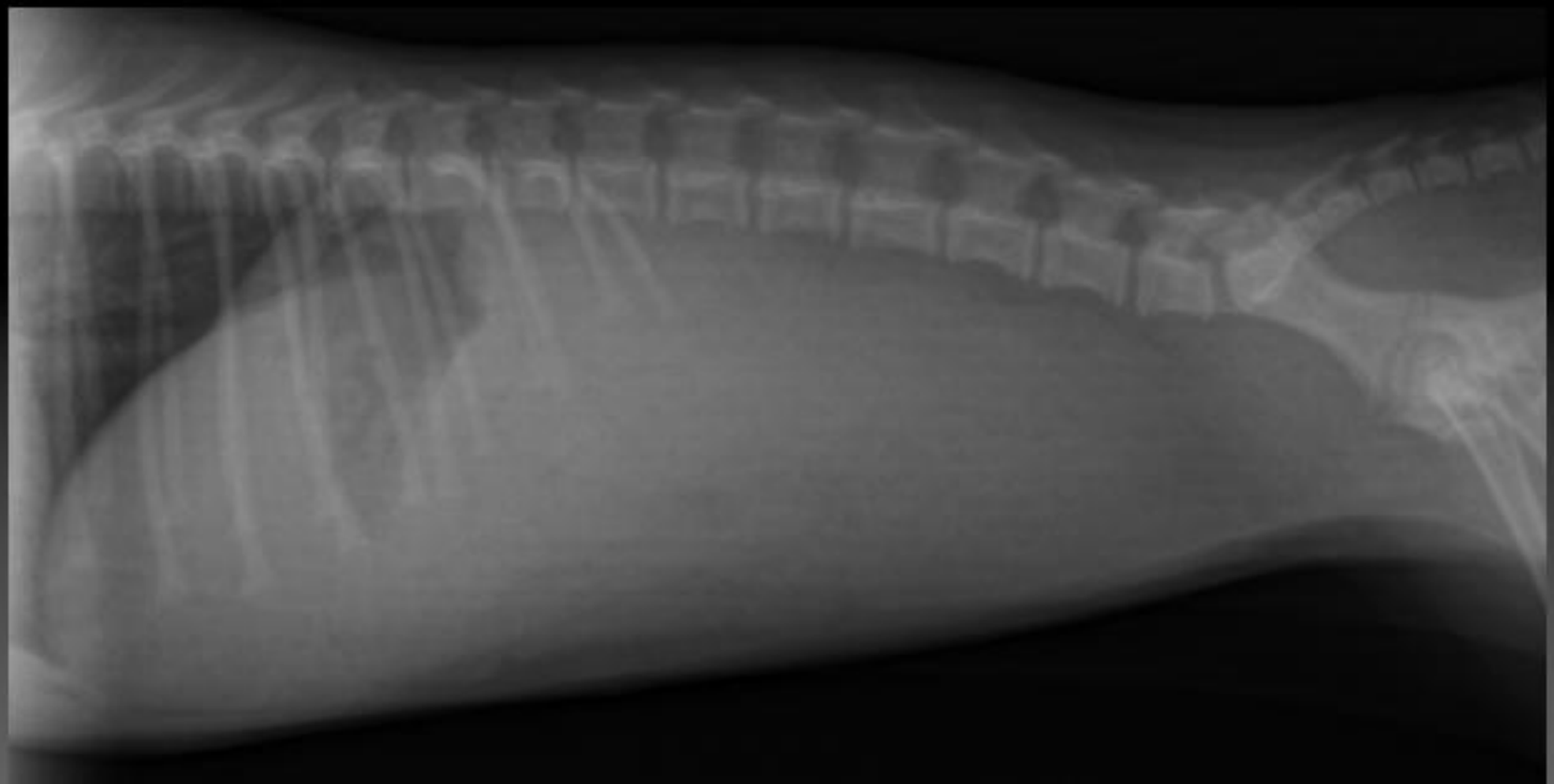

Serosal Detail

- Causes for loss of serosal detail
  1. Decreased fat (thin animal)
  2. Abdominal effusion
  3. Mass effect
  4. Peritonitis
  5. Young animal

Underexposure

Liver

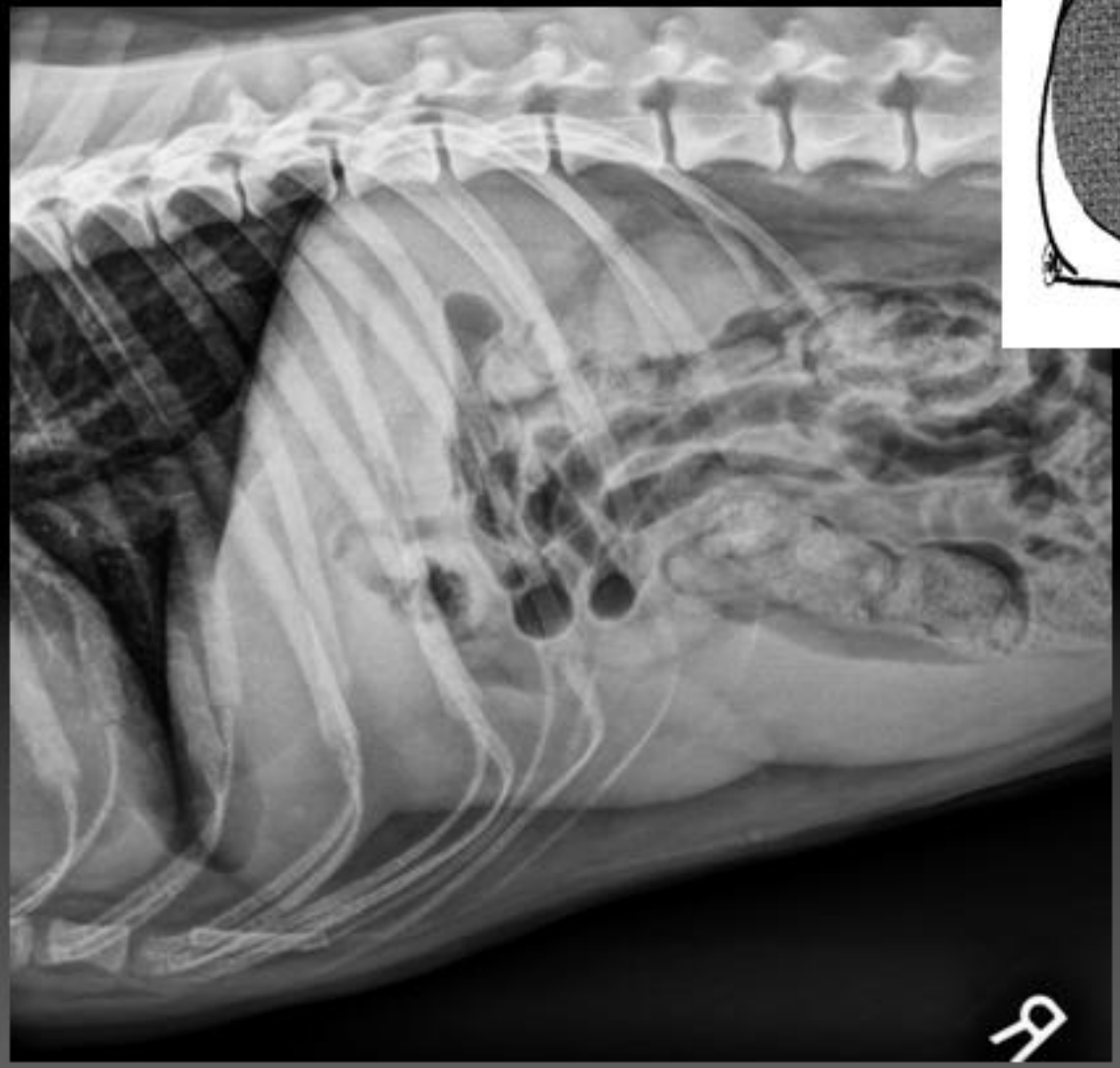

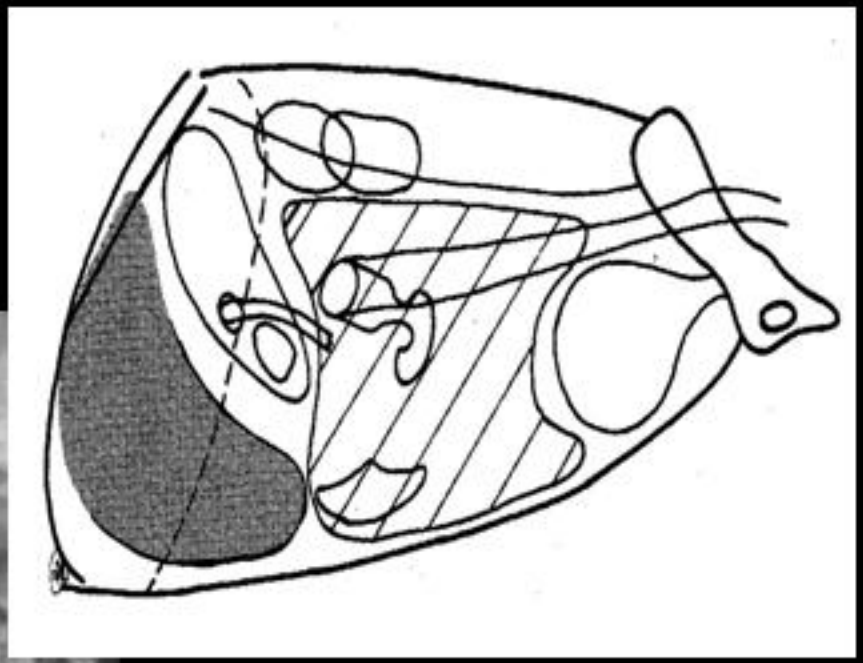

Liver

- Size
  - Gastric Axis
  - Costal Arch
- Shape
  - Sharp margin vs. blunted, rounded border
- Opacity
  - Soft tissue

Hepatomegaly

Microhepatia

- Cranial shift in gastric axis
- Cranial displacement of intestines and stomach on VD

Microhepatia

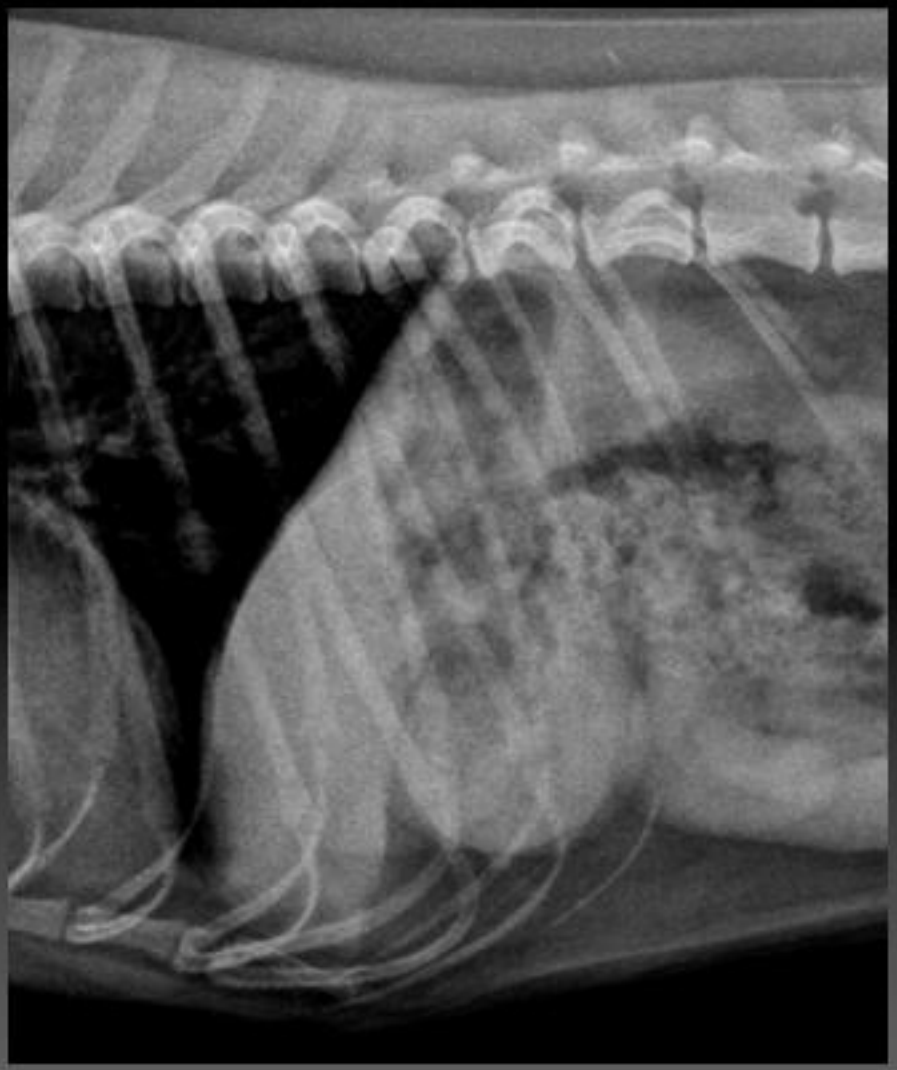

Opacity

Stomach

- Anatomy

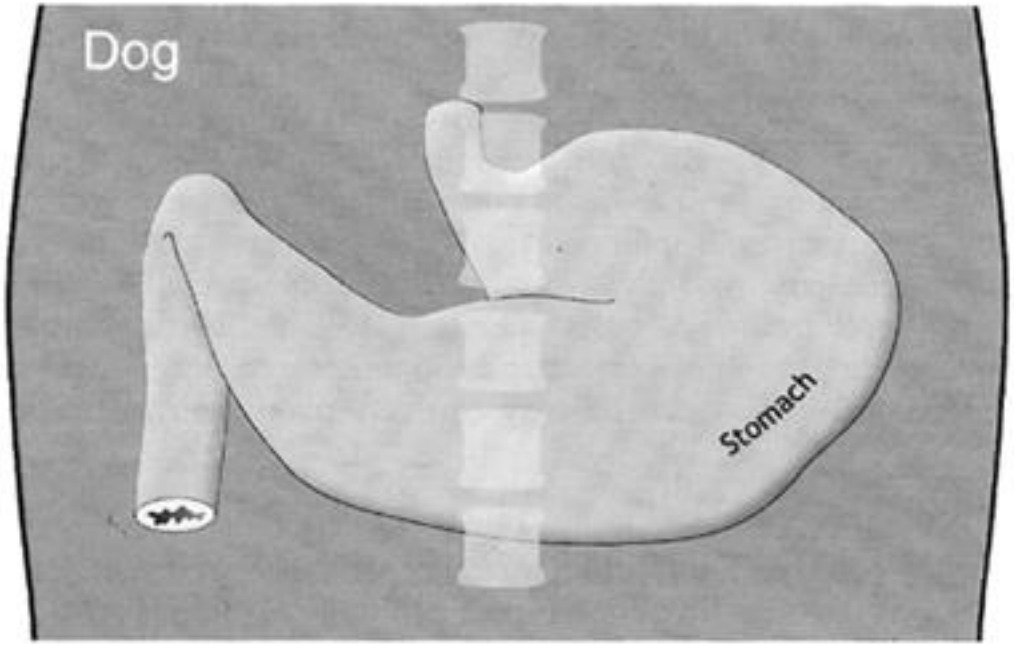

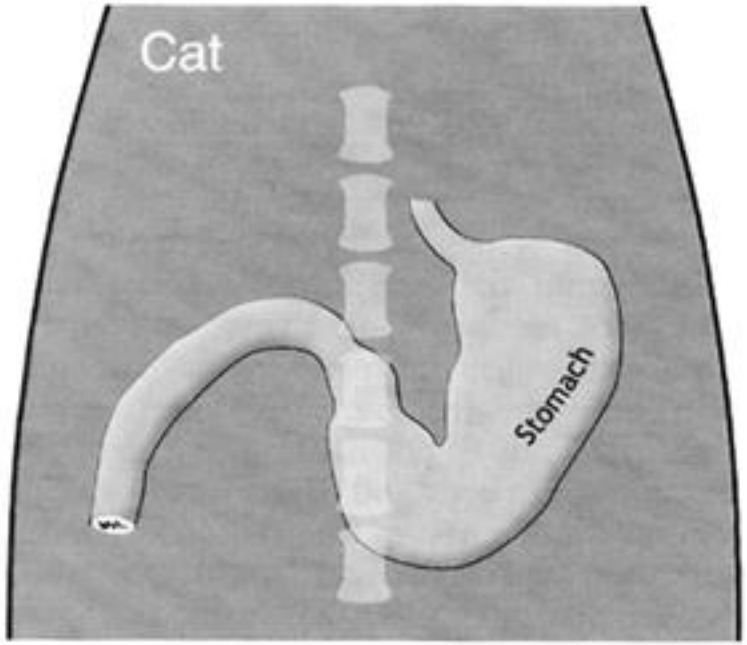

Stomach

- Rt vs. Lt lateral

Stomach

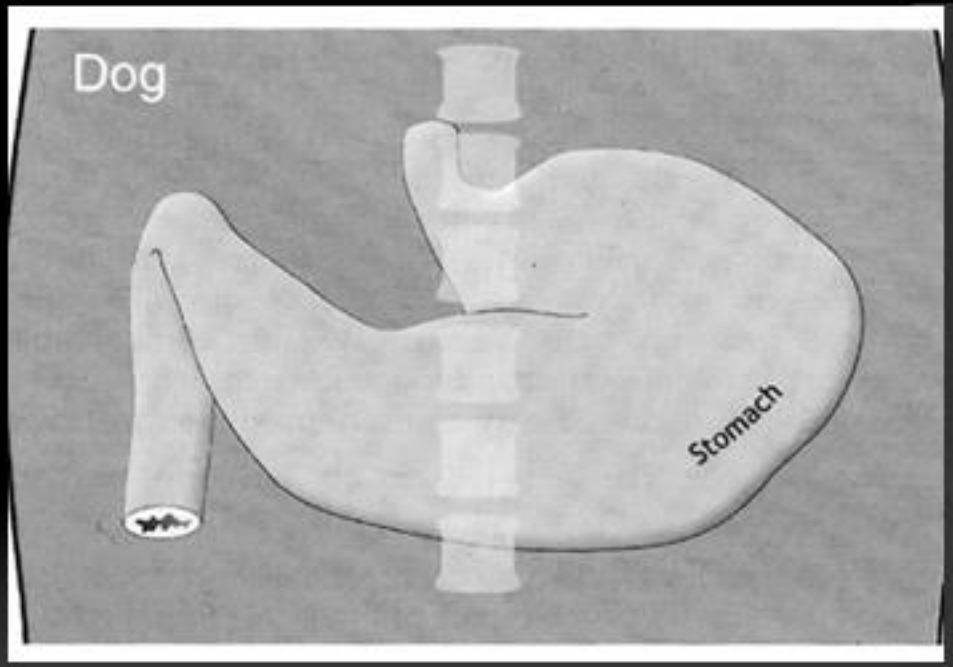

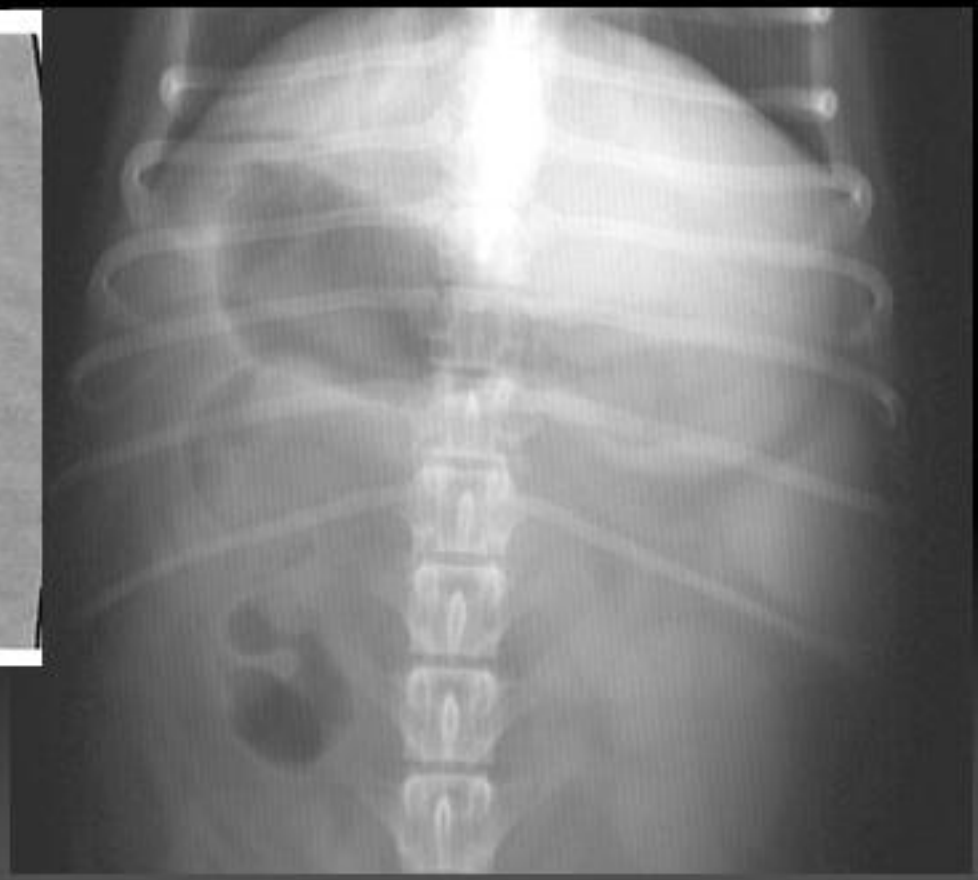

Gastric Dilation and Volvulus

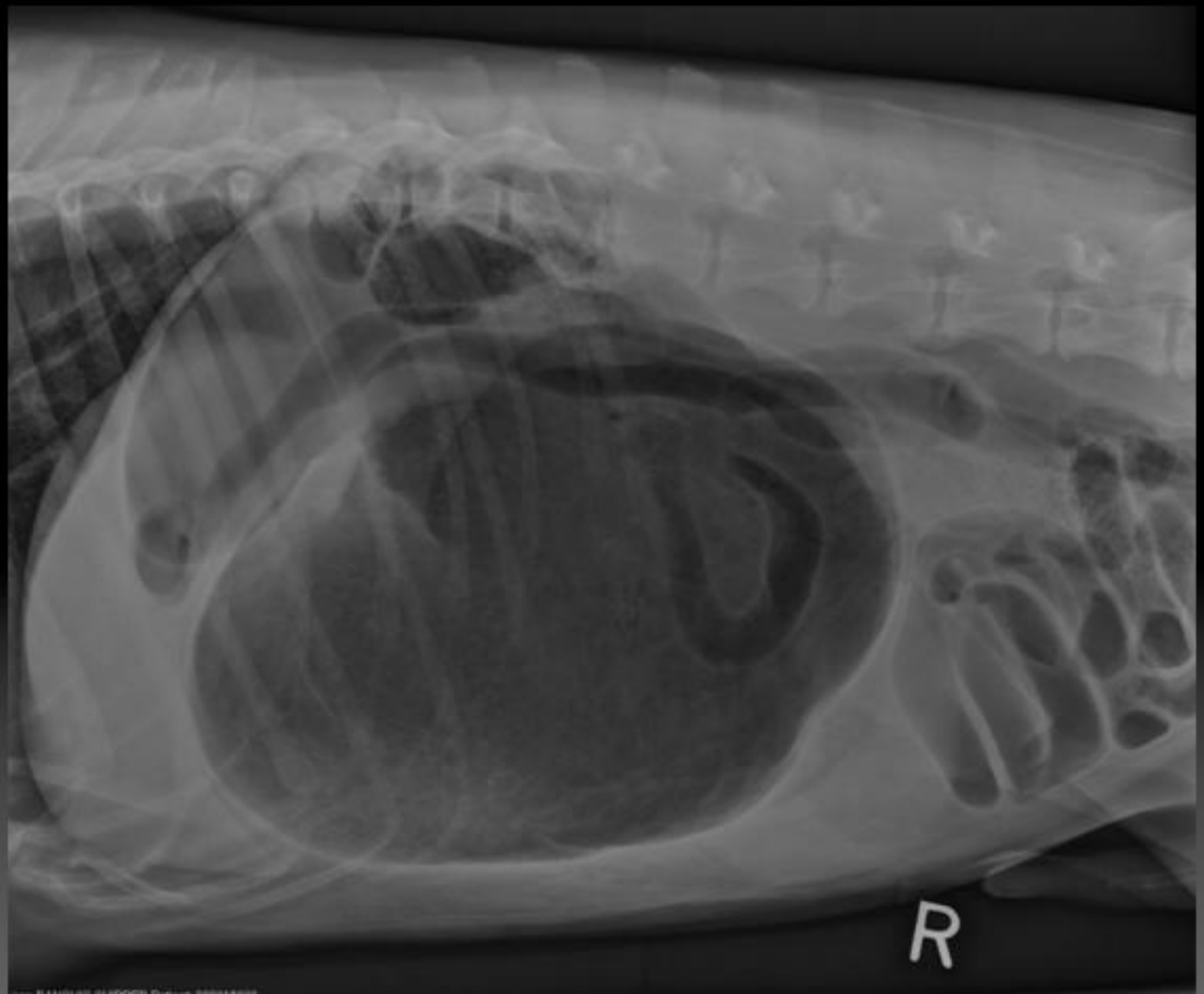

GDV

- Pylorus malpositioned dorsally and to the right
- Surgical Emergency
- Right lateral view is most productive
- DV may also help (GDV)

GDV vs. Gastric Dilation

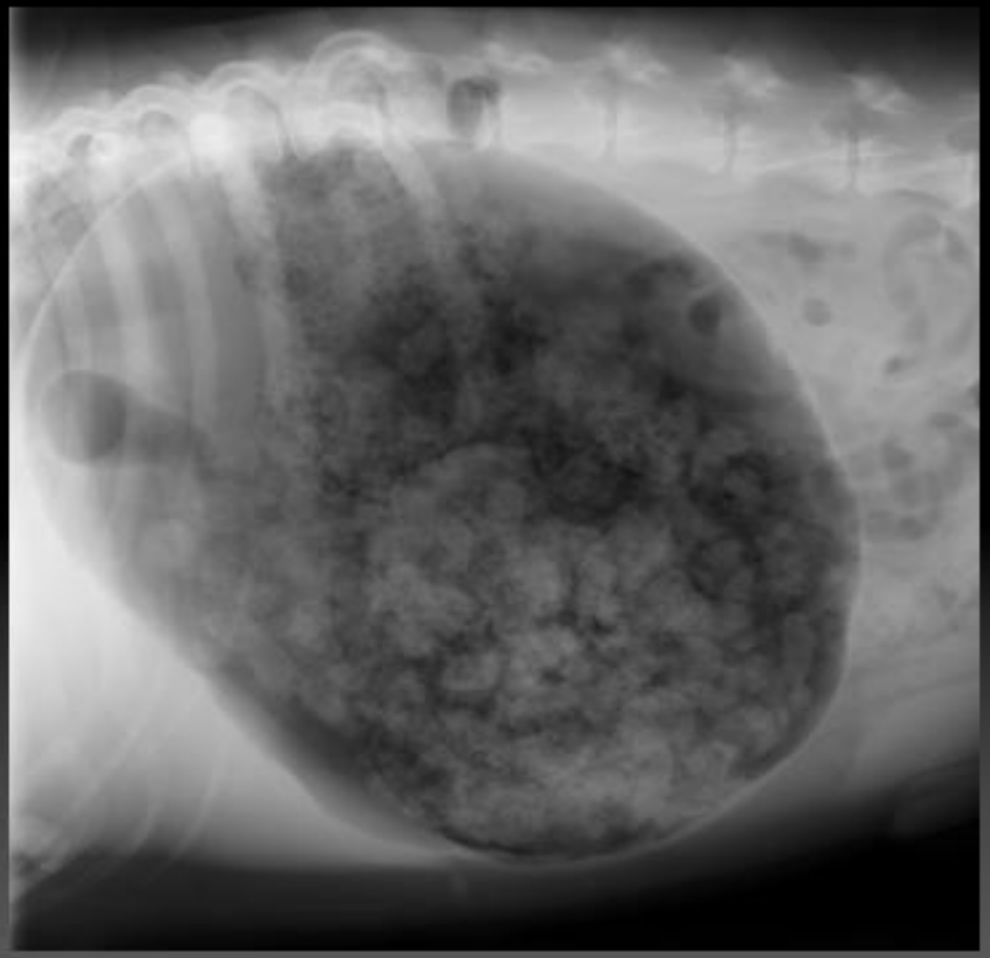

GDV trns

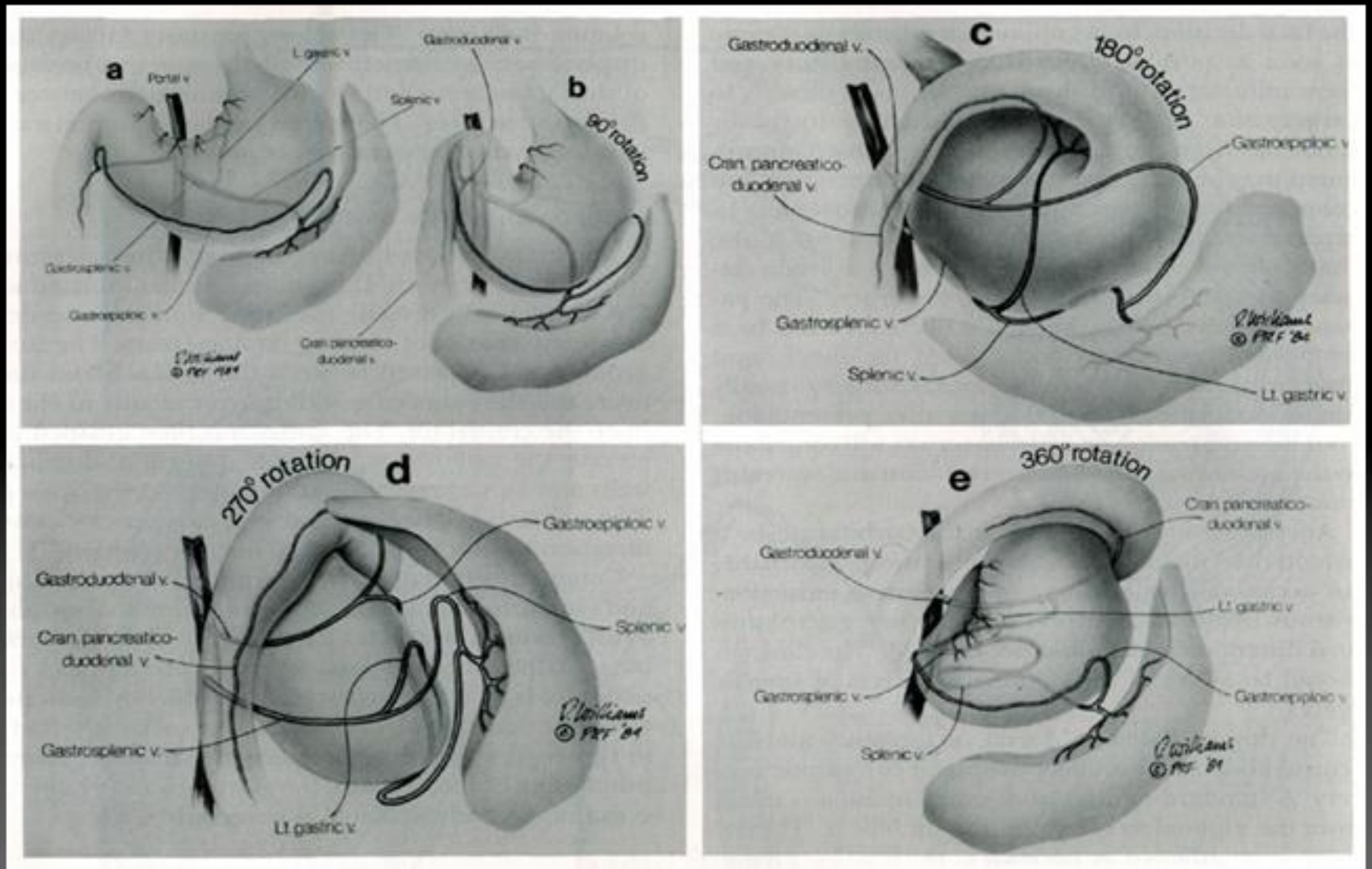
a
Portal v.
L. gastric v.
Gastroduodenal v.
Splenic v.
Gastrosplenic v.
Gastroepiploic v.
Cran. pancreatico-duodenal v.
b
90° rotation
c
180° rotation
Gastroduodenal v.
Cran. pancreatico-duodenal v.
Gastroepiploic v.
Gastrosplenic v.
Splenic v.
Lt. gastric v.
d
270° rotation
Gastroduodenal v.
Cran. pancreatico-duodenal v.
Gastroepiploic v.
Splenic v.
Gastrosplenic v.
Lt. gastric v.
e
360° rotation
Cran. pancreatico-duodenal v.
Gastroduodenal v.
Lt. gastric v.
Gastrosplenic v.
Gastroepiploic v.
Splenic v.

GDV

R vs. L Lateral

Gastric Foreign Body

- Rt vs. Lt lateral view

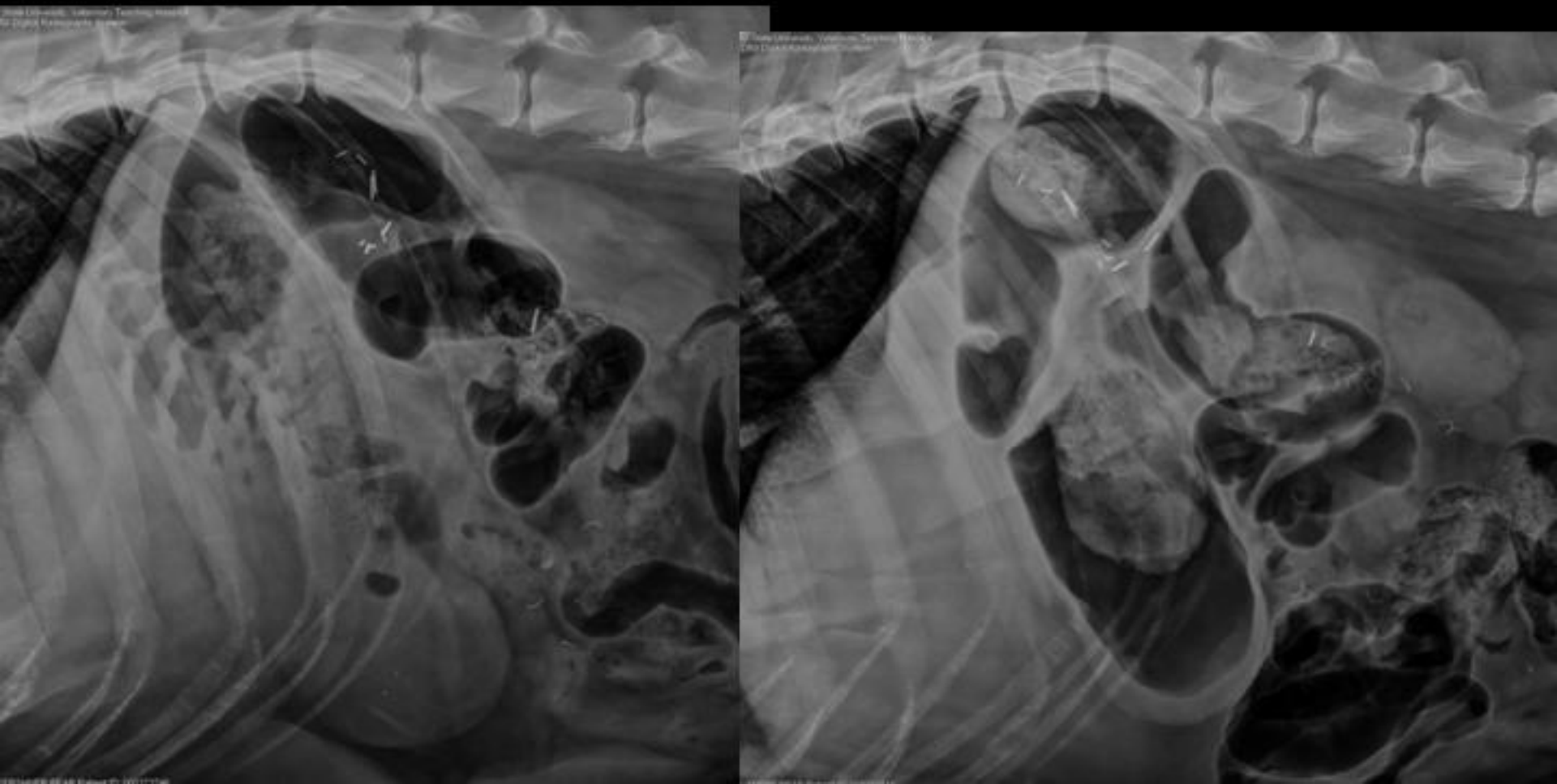

Outflow Obstruction

Spleen

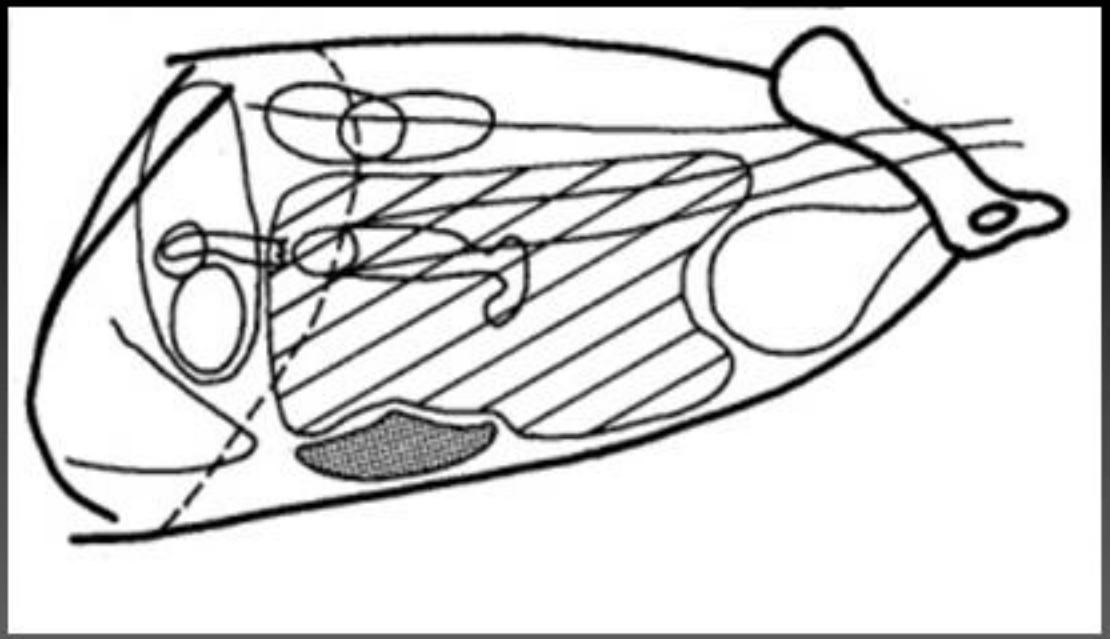

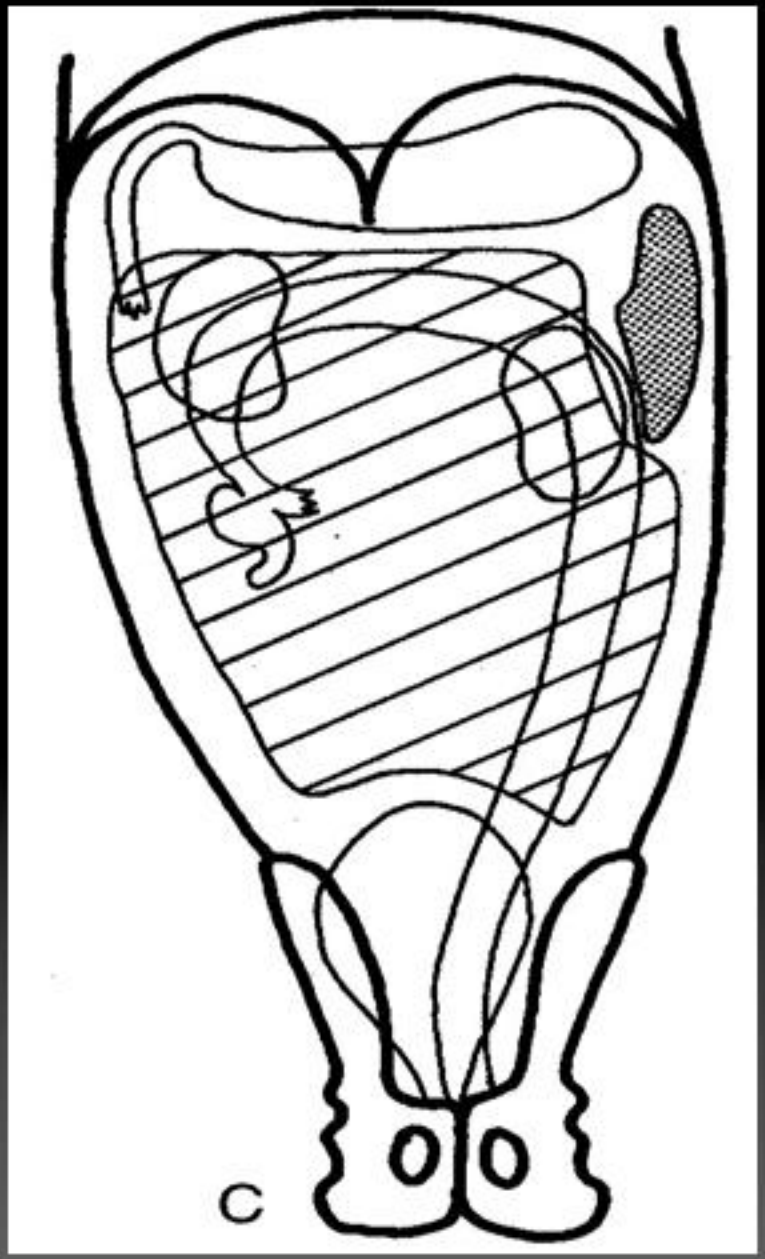

Spleen

- Size
  - Highly variable
  - Cats should not appear on right lateral view
  - Cats < 1.5 cm thick on US

Splenomegaly

Lymphoma

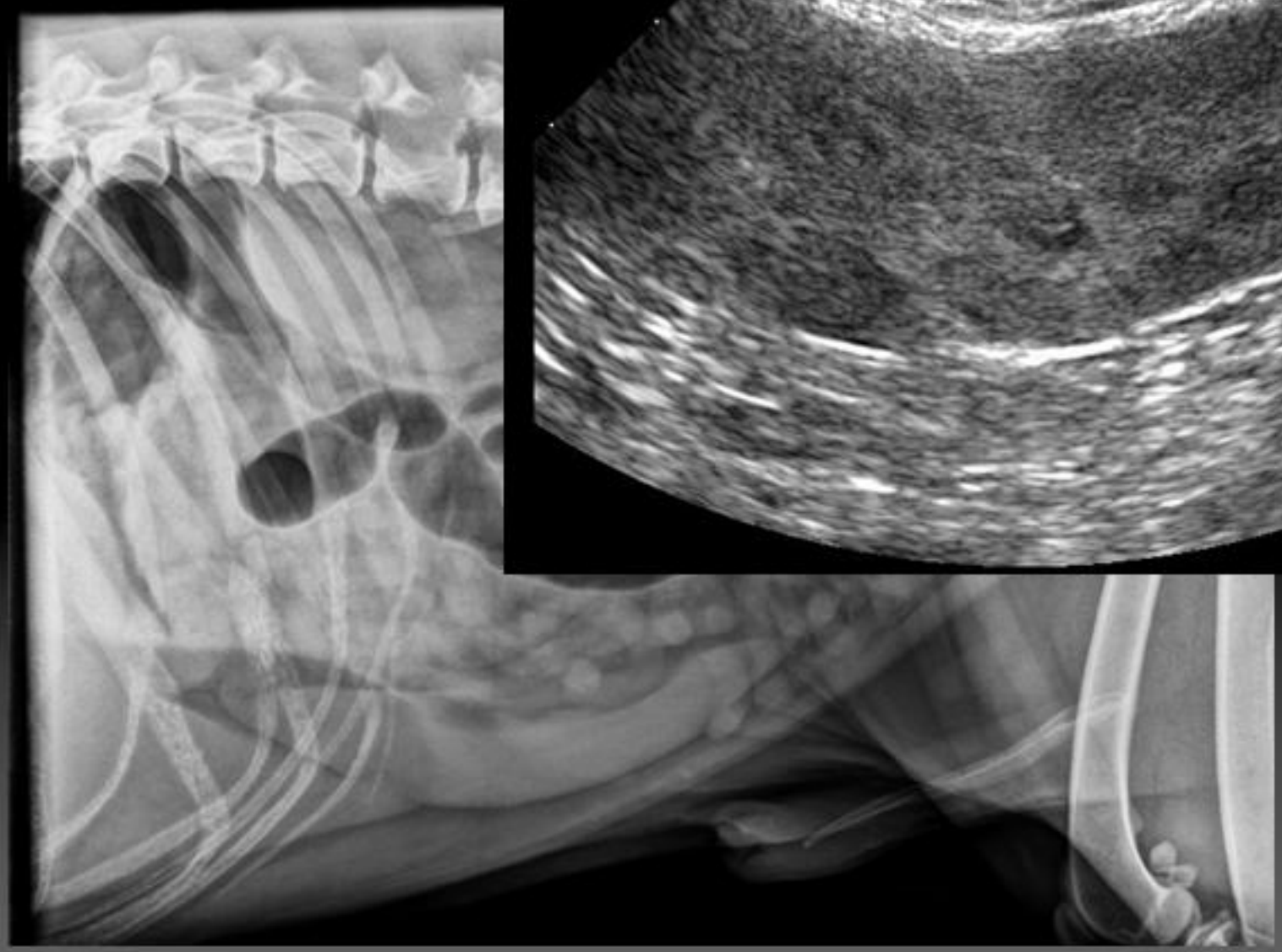

Small Intestine Size

- Dogs
  - < 1.5 times height of L5
- Cats
  - ≤ 12 mm
- Ileus- generic term for enlarged bowel
- Cannot determine bowel wall thickness on survey radiographs

Mechanical vs. Functional Ileus

- Mechanical
  - Non uniform population of small intestines
  - Not all are increased in size
  - Focal or several loops of bowel
- Functional Ileus
  - Uniform, generalized dilation of bowel
  - Often gas filled

SI Obstruction

SI Obstruction

Ileus- Functional

UGI Interpretation

- Intraluminal foreign body