

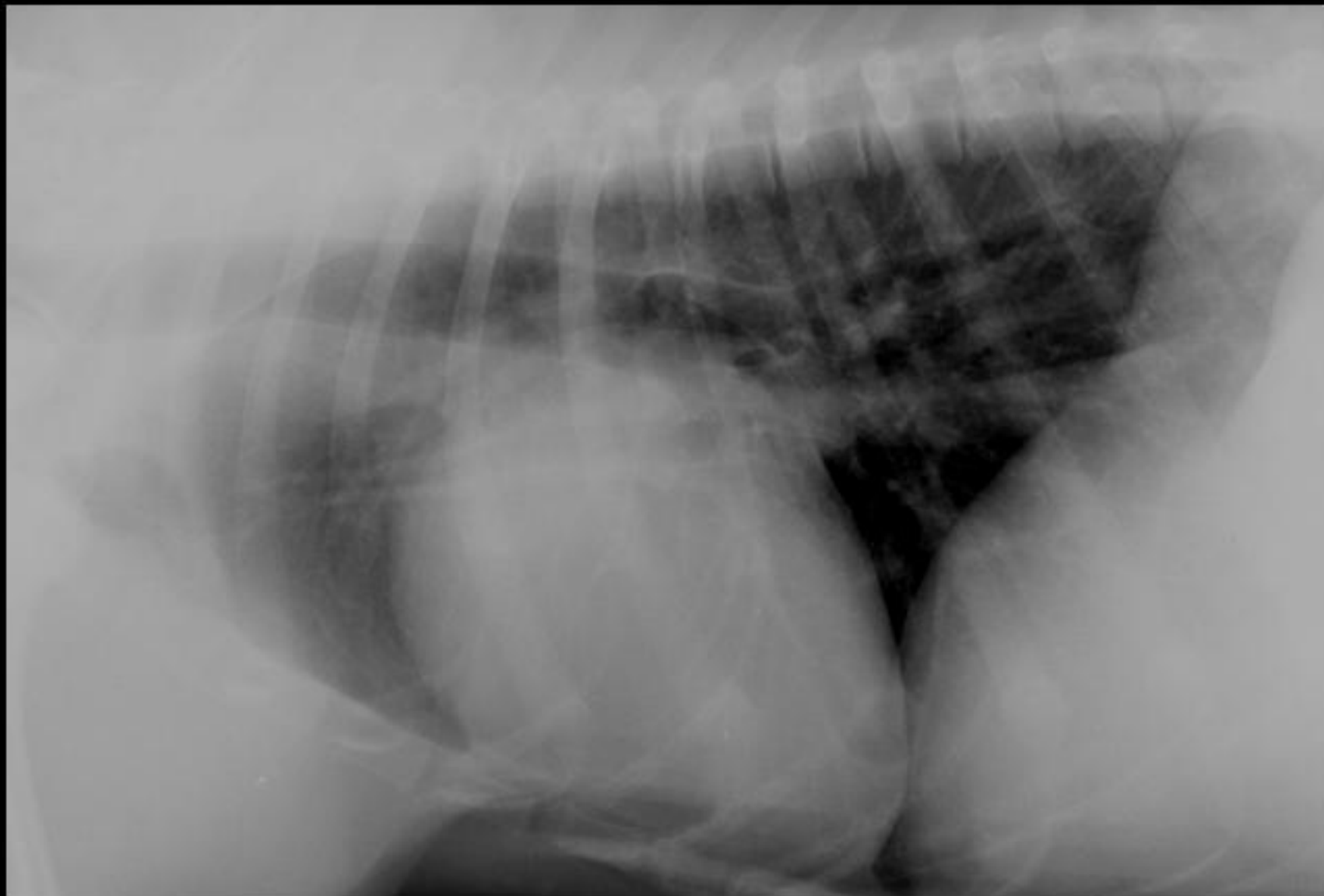
LA Enlargement

- ▣ Causes:
 - Mitral Insufficiency
 - ▣ Endocardiosis
 - ▣ Dysplasia
 - Patent Ductus Arteriosus
 - Dilated Cardiomyopathy (mostly dogs)
 - Hypertrophic Cardiomyopathy (cats)

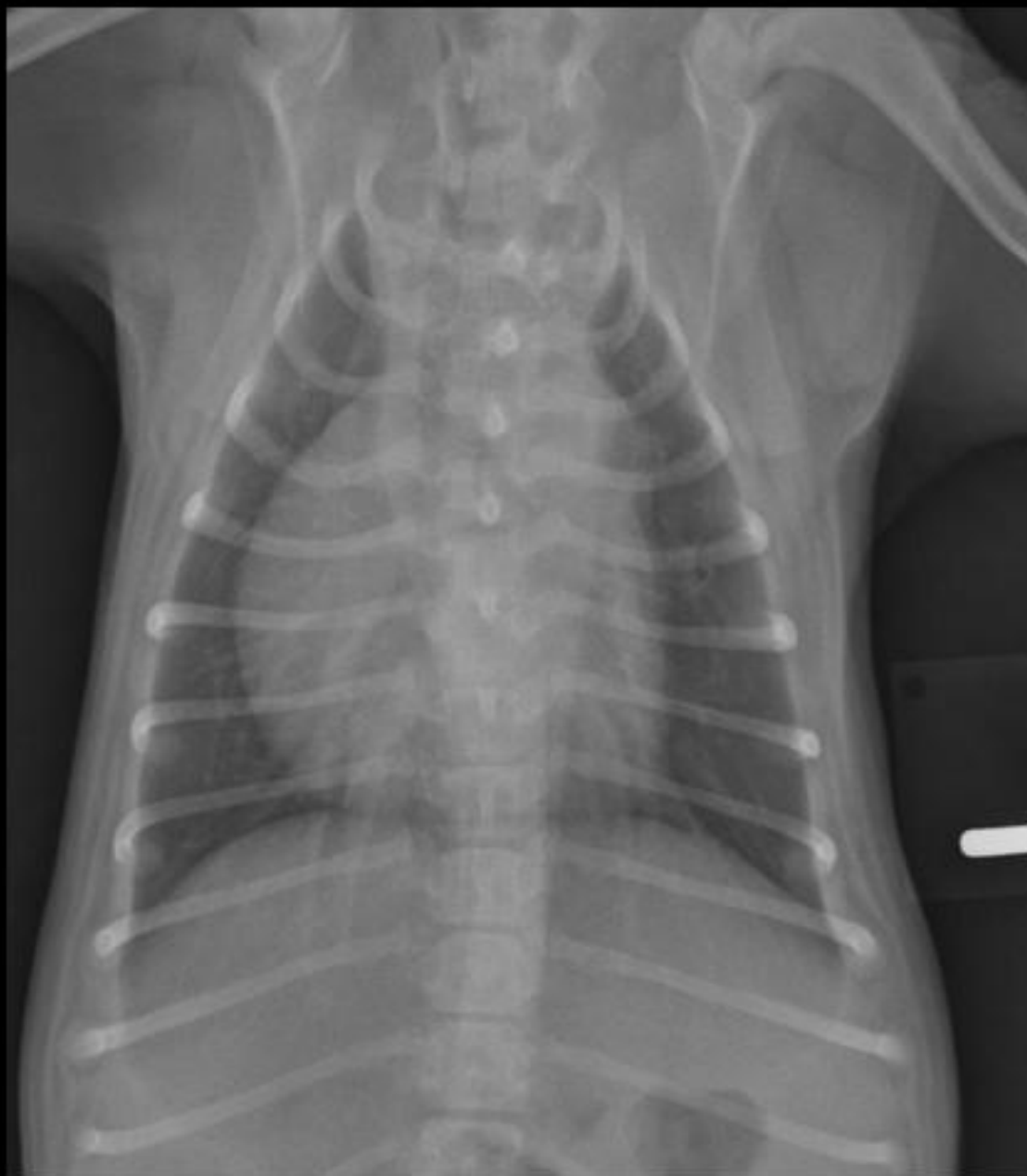Right Ventricular Enlargement

- ▣ **Greater than 3 intercostal spaces wide**
 - $< 3 \frac{1}{2}$ for brachycephalic breeds (ie Eng Bulldogs)
 - $< 2 \frac{1}{2}$ for deep-chested breeds (ie Doberman)
 - Increased sternal contact is measured in intercostal spaces
- ▣ **Rounded and full RV on VD view (6-9 o'clock)**
 - Reverse D on VD view

RV Enlargement



RV
Enlargement



RV Enlargement

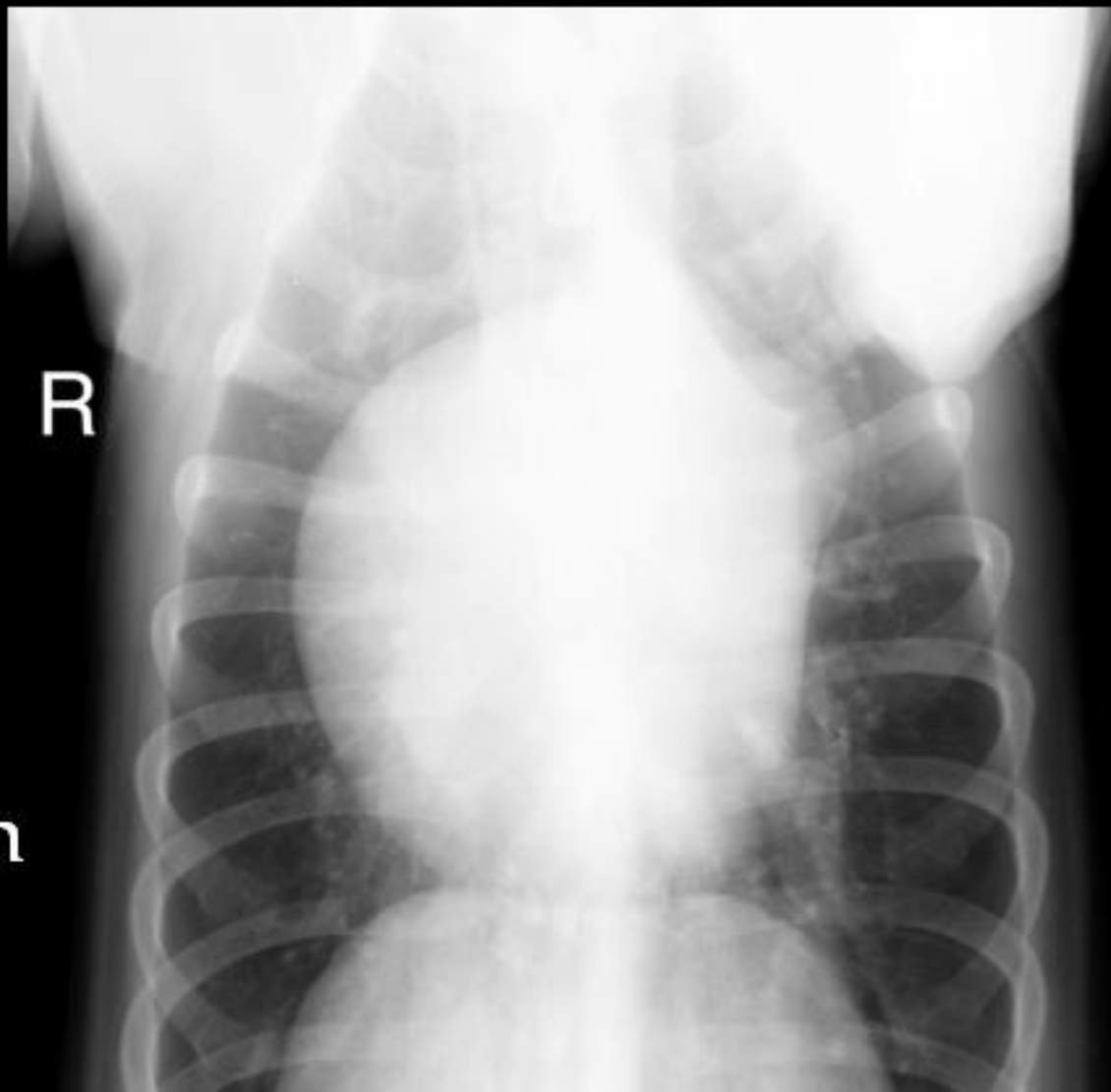
▣ Causes:

- Pulmonic Stenosis (with MPA enl.)
- Heart Worm
- Pulmonary Hypertension
- Tricuspid insufficiency
- Tetralogy of Fallot
- Second to Left Heart Failure
- Dilated Cardiomyopathy

RA enlargement alone is rare, seen with tricuspid dysplasia

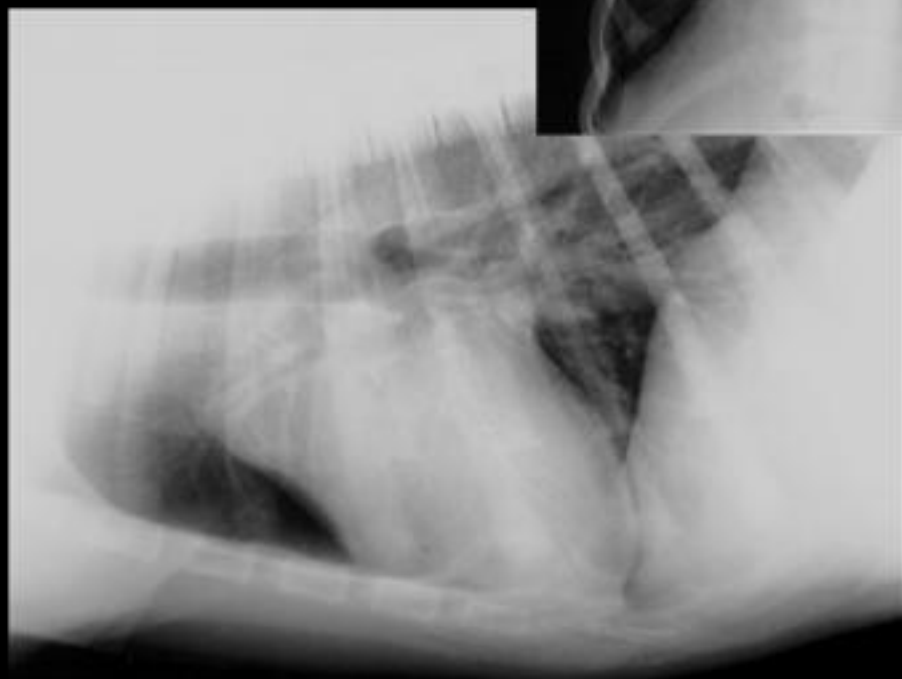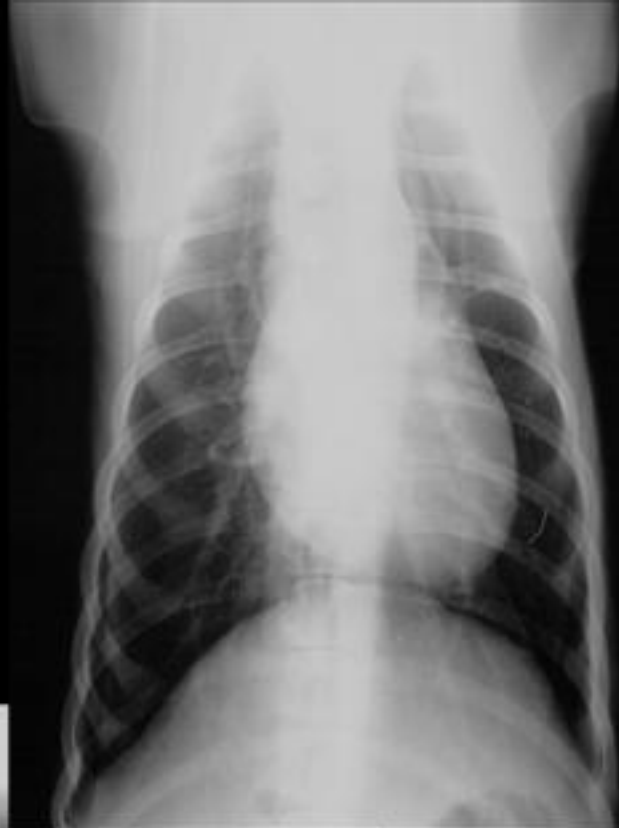Main Pulmonary Artery “Bulge” (aneurysmal dilation)

- ▣ 2 o'clock
- ▣ Causes:
 - PDA
 - PS
 - HW
 - Pulmonary hypertension



Aortic “Bulge”

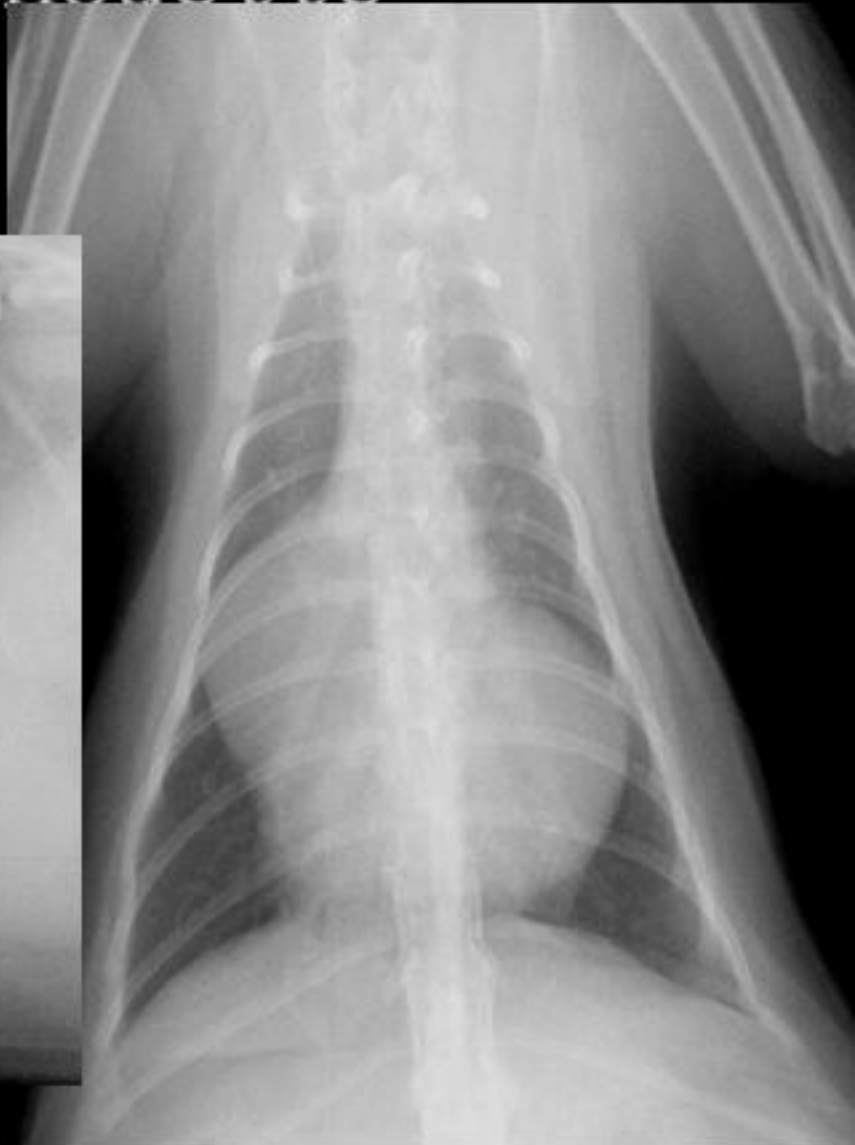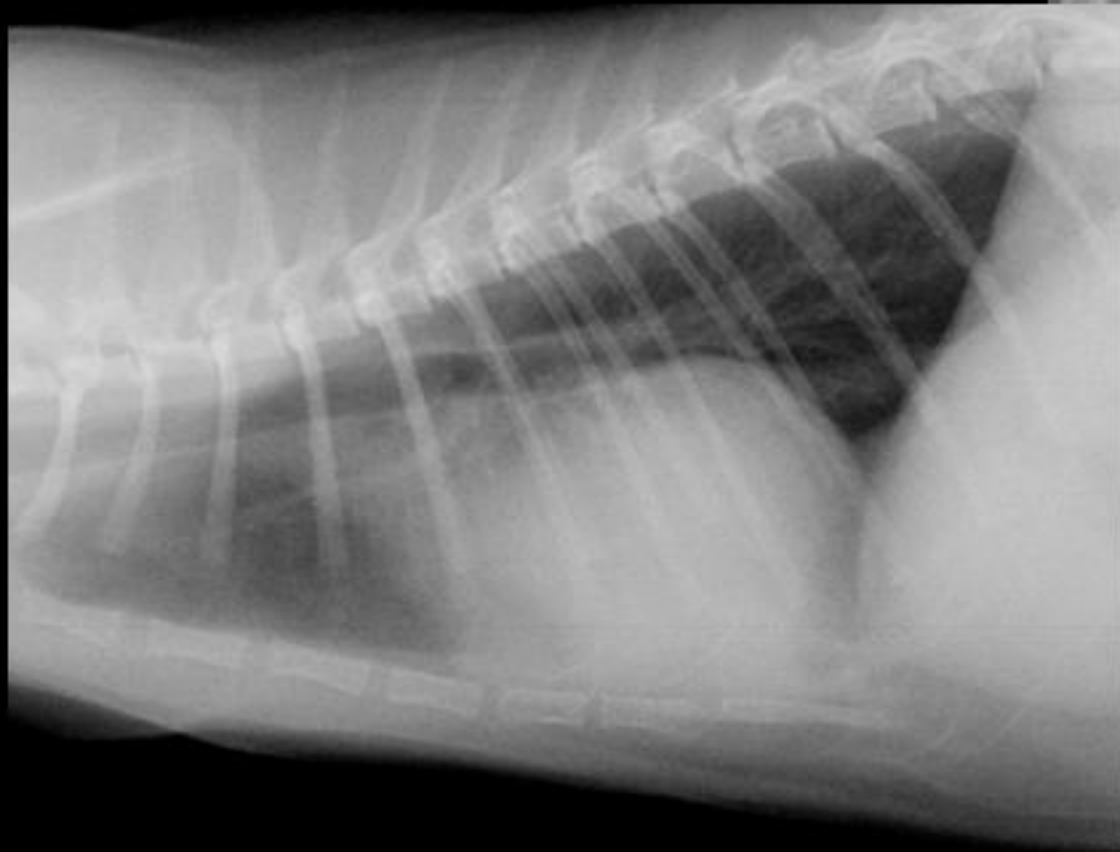- ▣ 1-2 o'clock
- ▣ Causes:
 - PDA
(descending aorta)
 - SAS (aortic arch)
 - Incidental in older cats



Globoid Silhouette

- ▣ Generalized cardiomegaly without distinct chamber enlargement.
- ▣ “Basketball” shaped heart

Globoid Silhouette

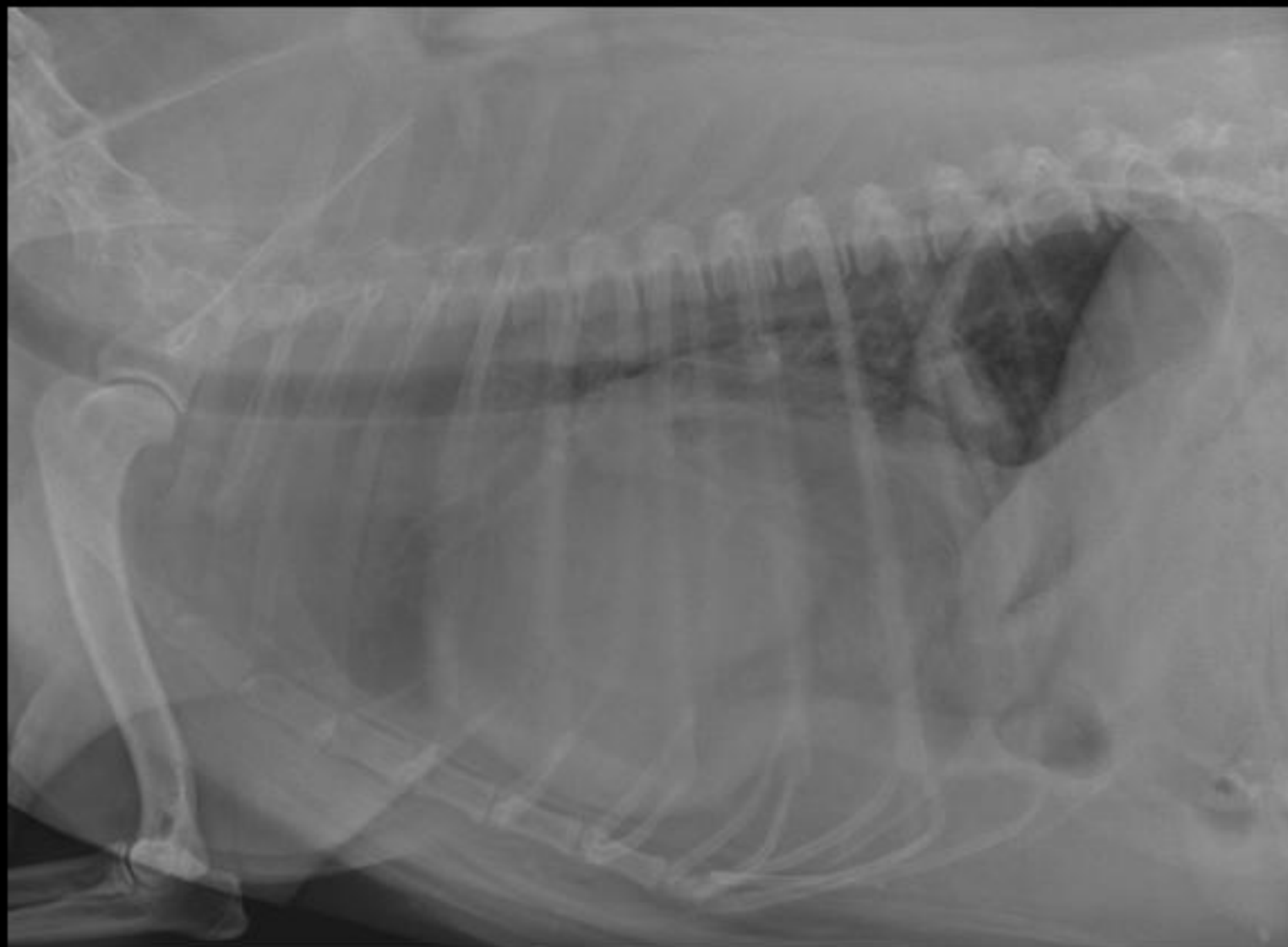

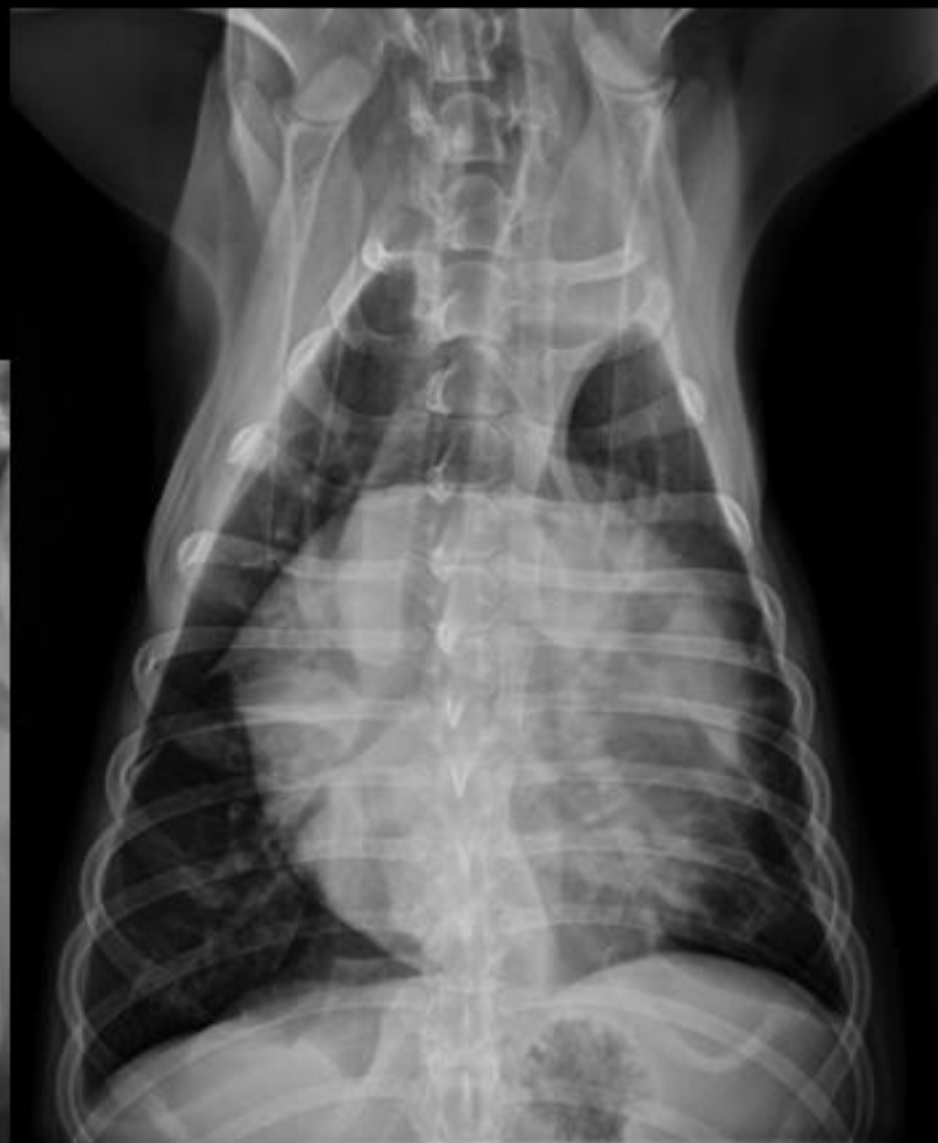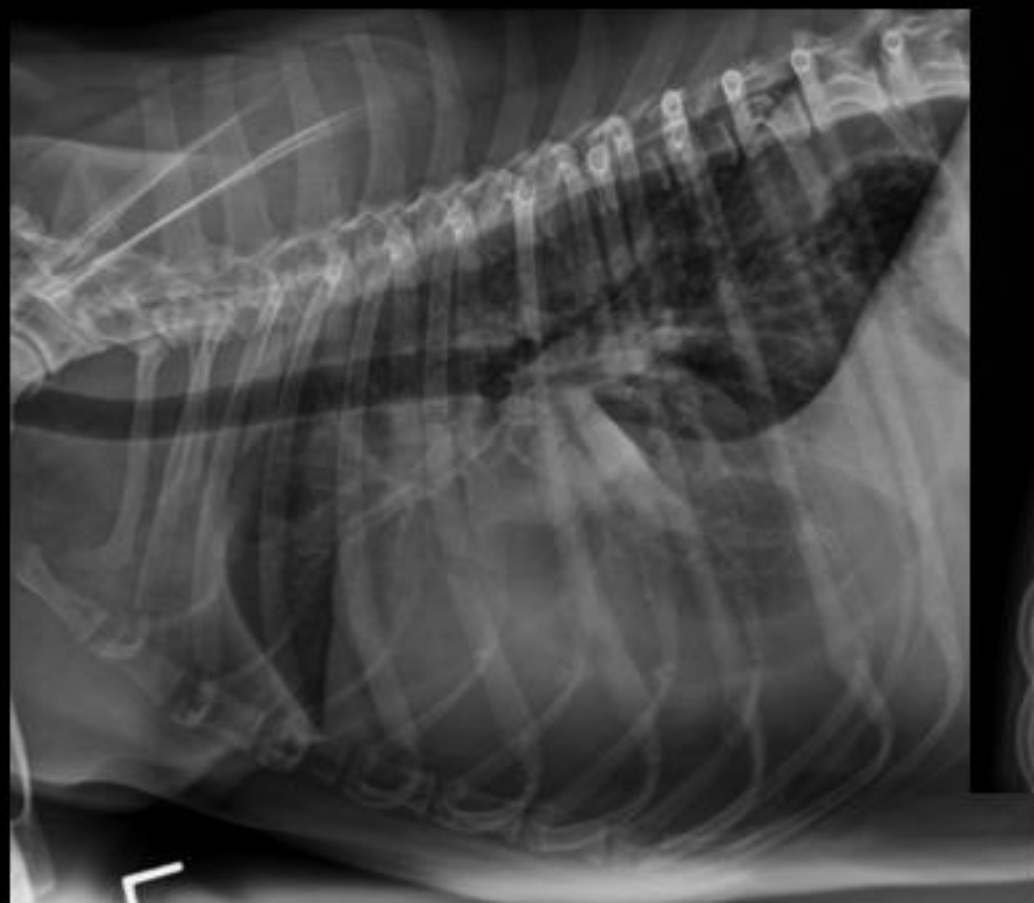Globoid Silhouette

▣ Causes:

- Pericardial effusion
- Severe DCM
- Peritoneopericardial Diaph Hernia
- Tricuspid dysplasia

Globoid Silhouette- Opacities

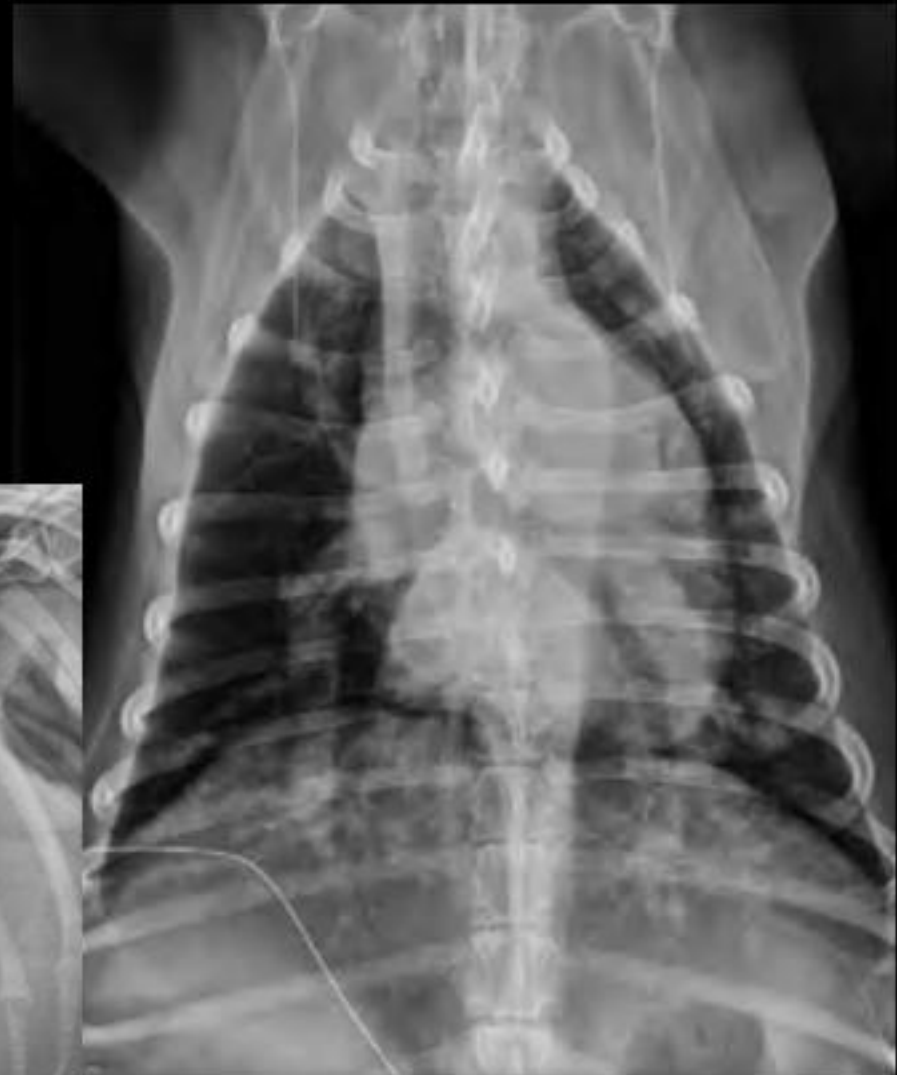
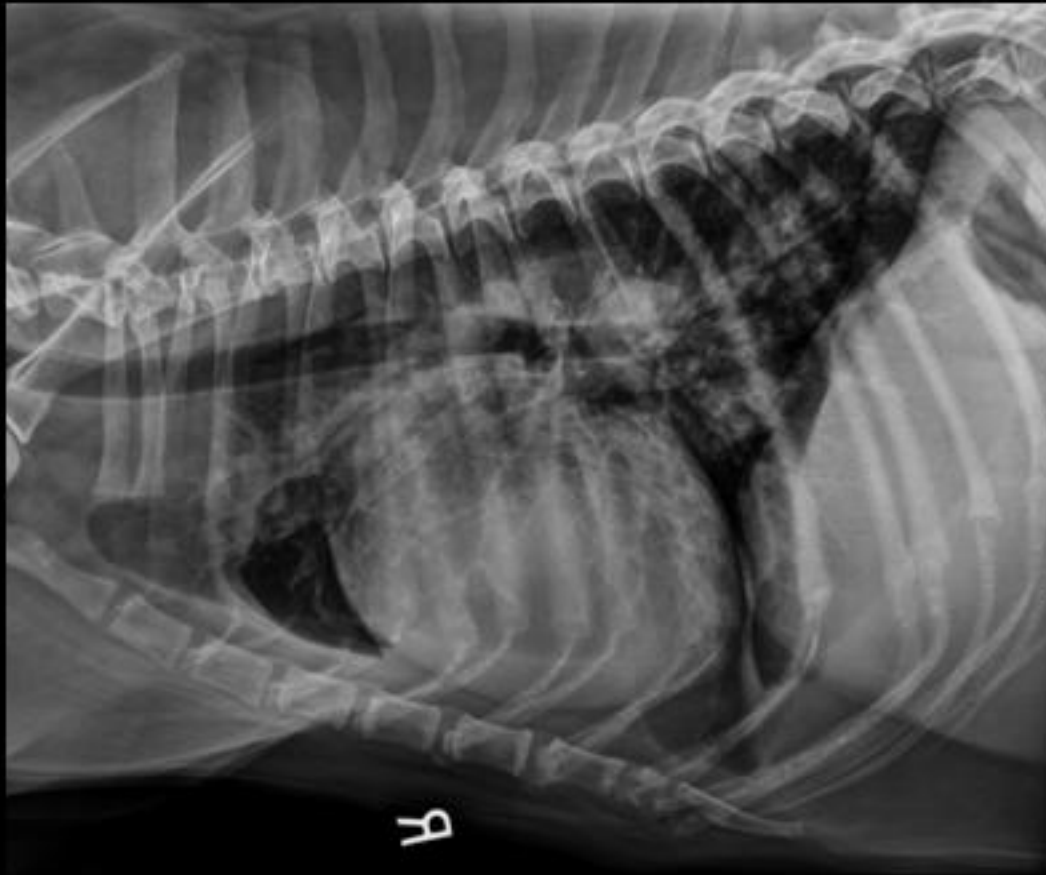


HW Radiographic Findings

- ▣ Pulmonary Arteries larger than Veins
- ▣ Right cardiac enlargement
- ▣ MPA Bulge (1-2 o'clock)
- ▣ Pulmonary Hypertension has similar radiographic appearance and may be present w/ HW

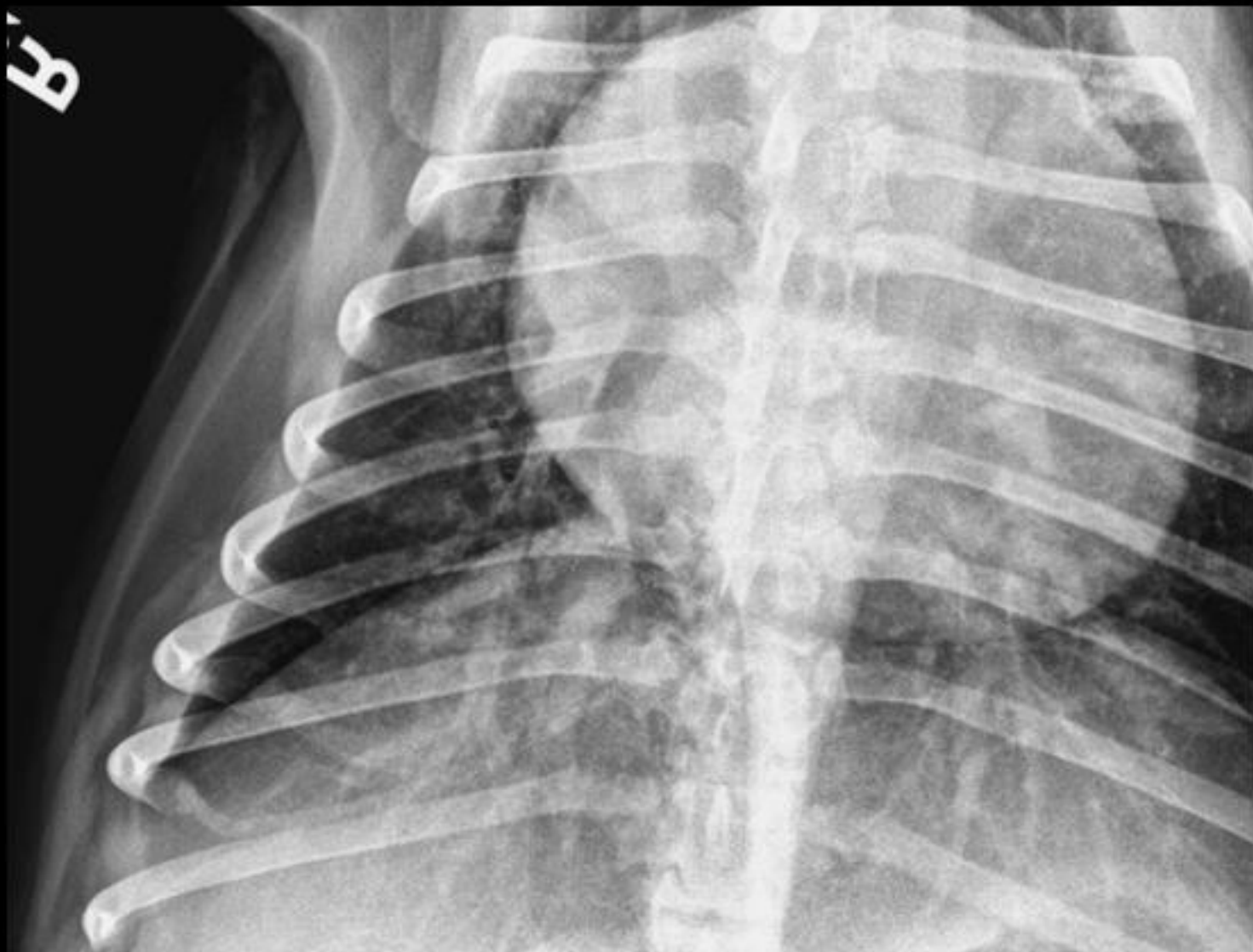Heart Worm



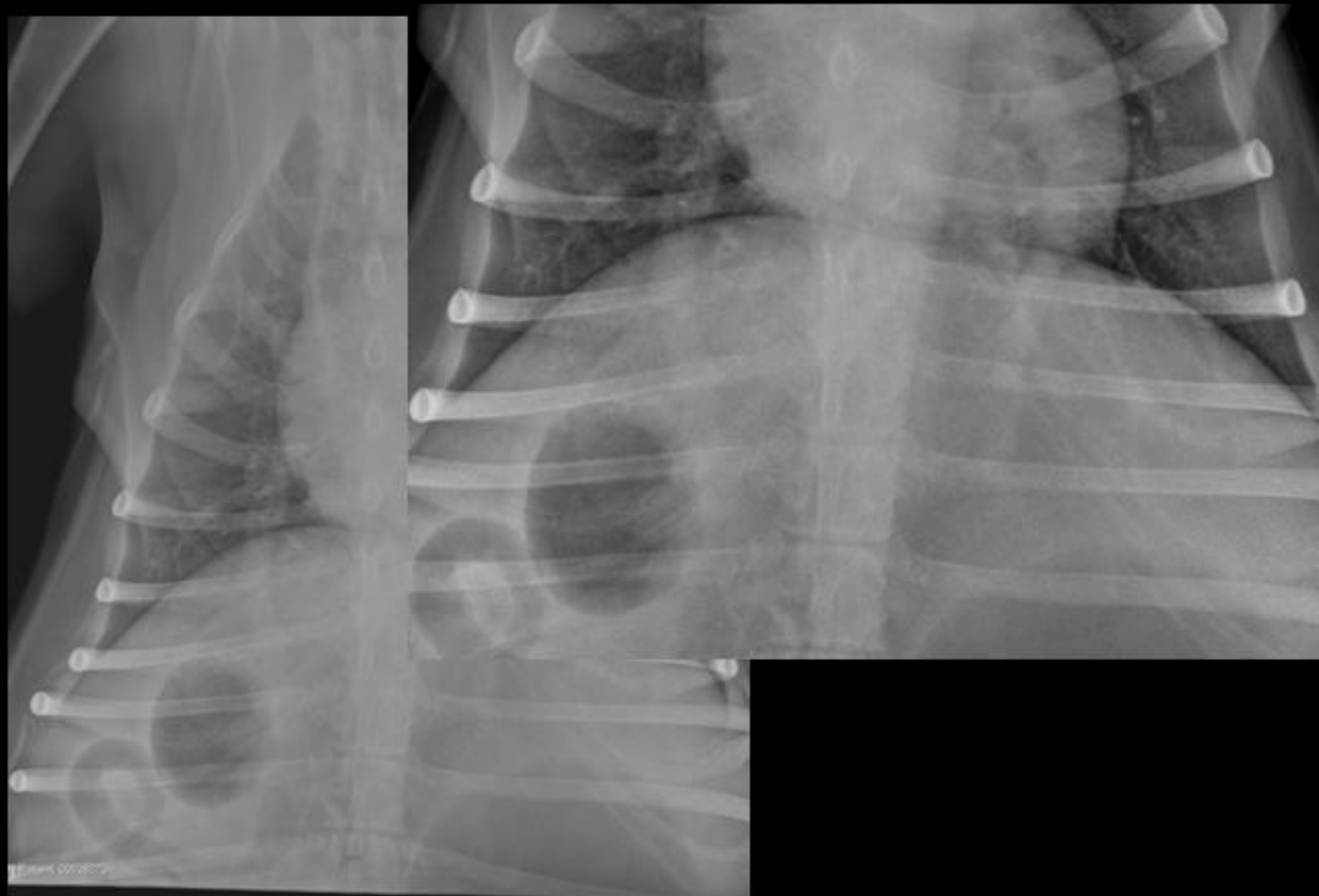
Pulmonary Vessels

- ▣ Veins are Central and Ventral
- Veins bigger than arteries
- Pulmonary venous congestion (L CHF)
 - ▣ Arteries bigger than veins
- Heart Worm, Pulmonary Hypertension
 - ▣ Arteries and veins both big
- Over circulation- congenital L to R shunt
 - ▣ Arteries and veins small to normal
- Underperfusion
- Hypovolemia, PS

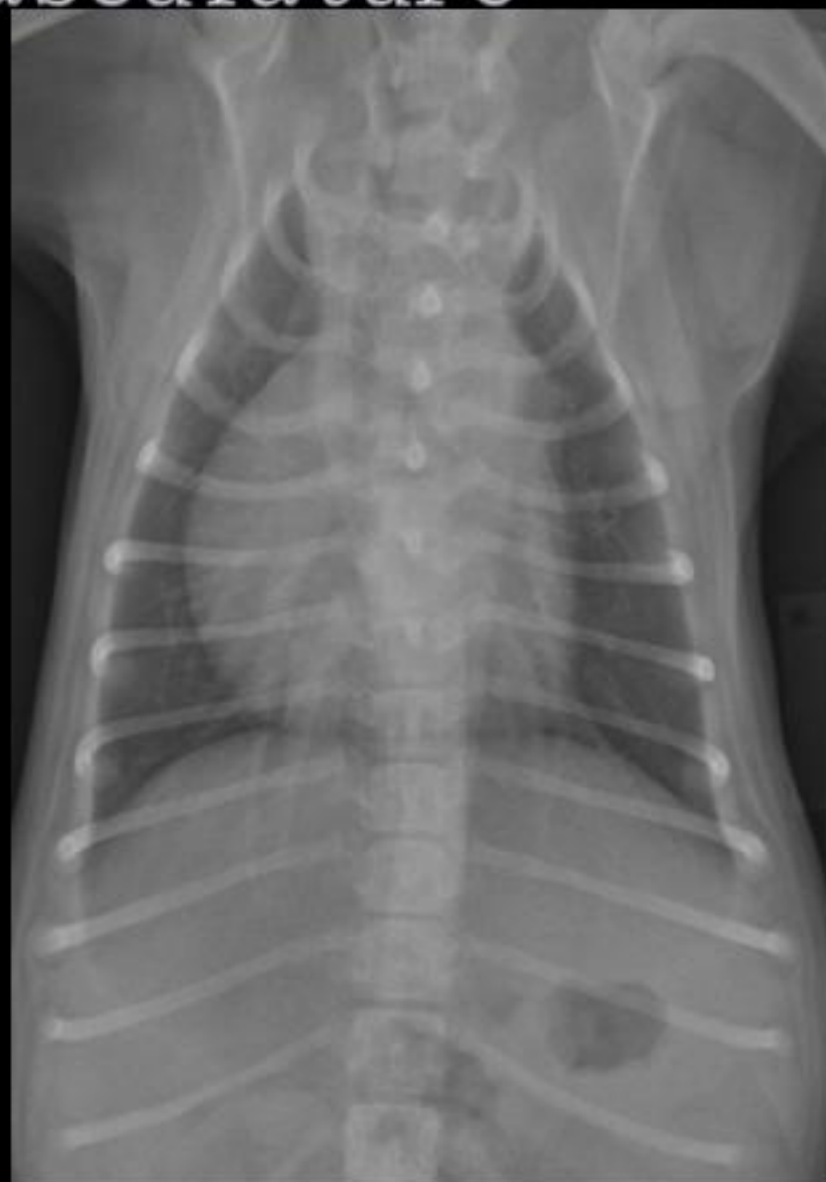
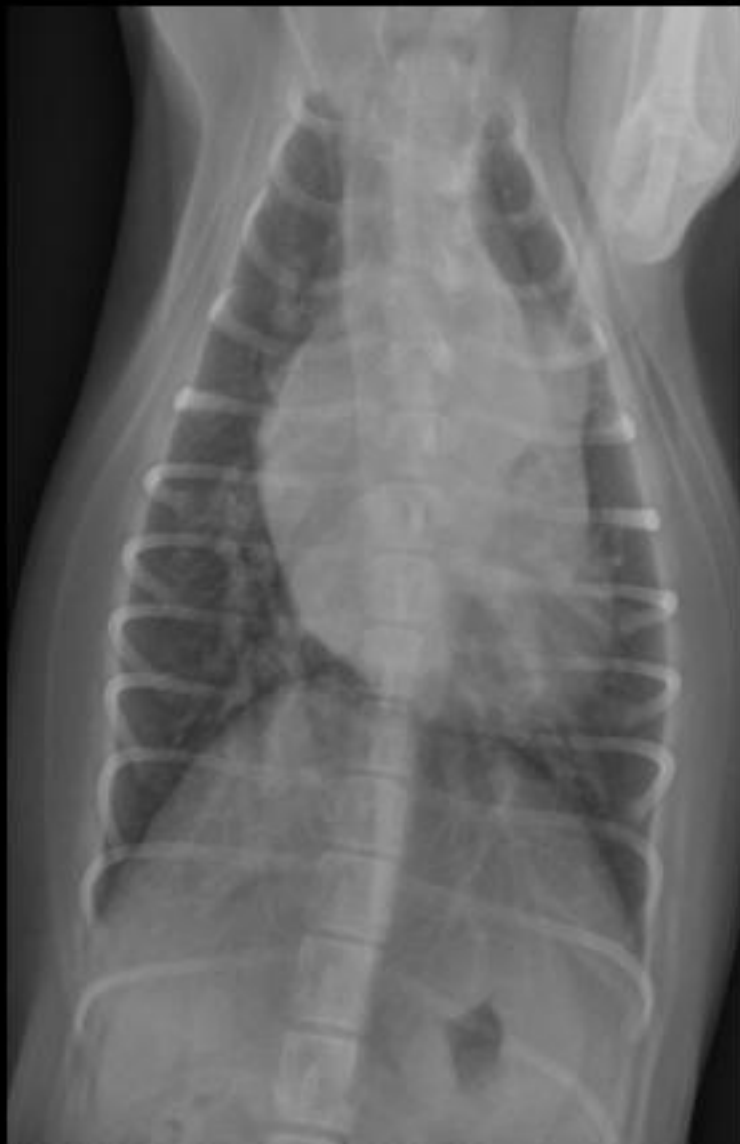Venous congestion



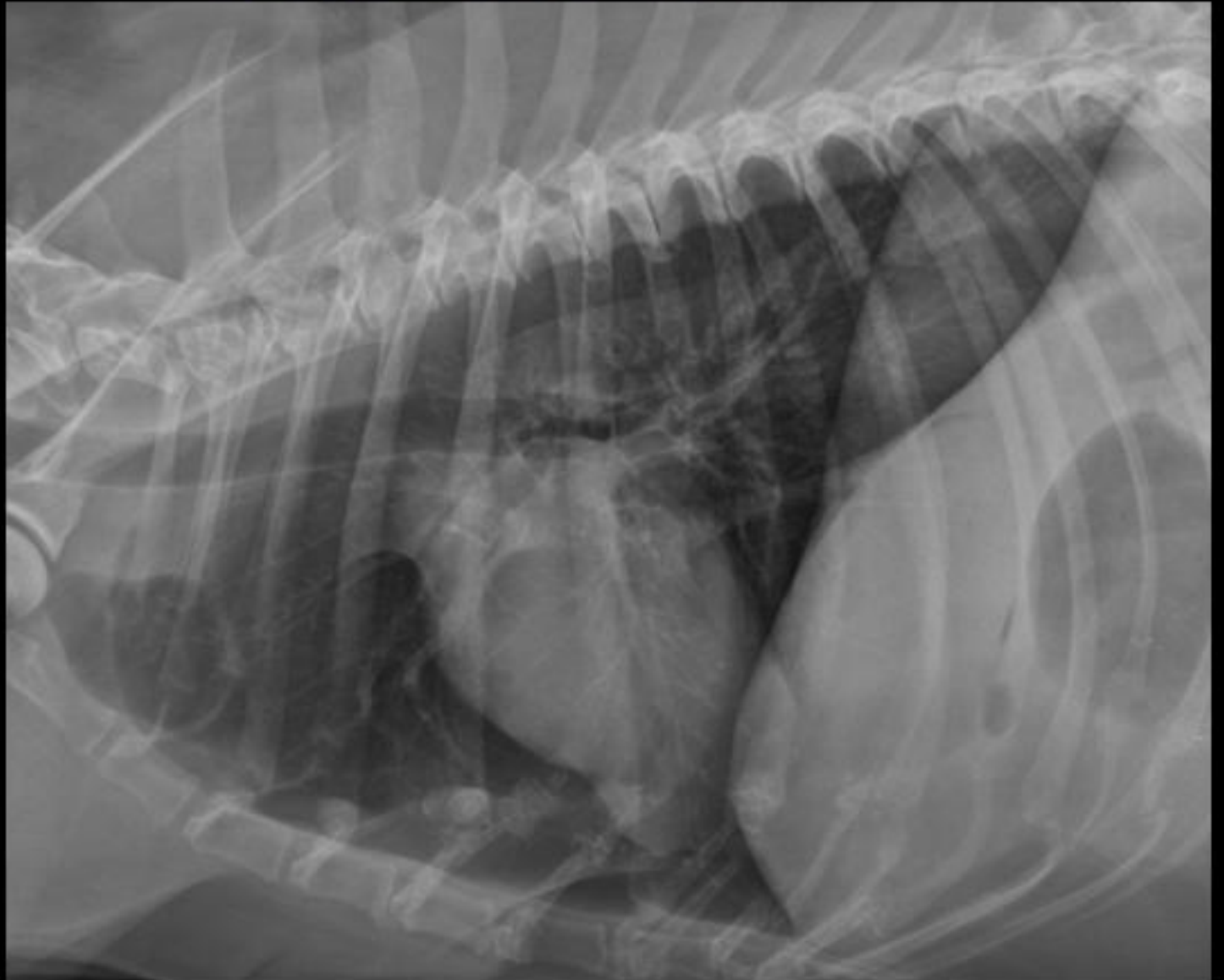
Pulmonary Arterial Enlargement



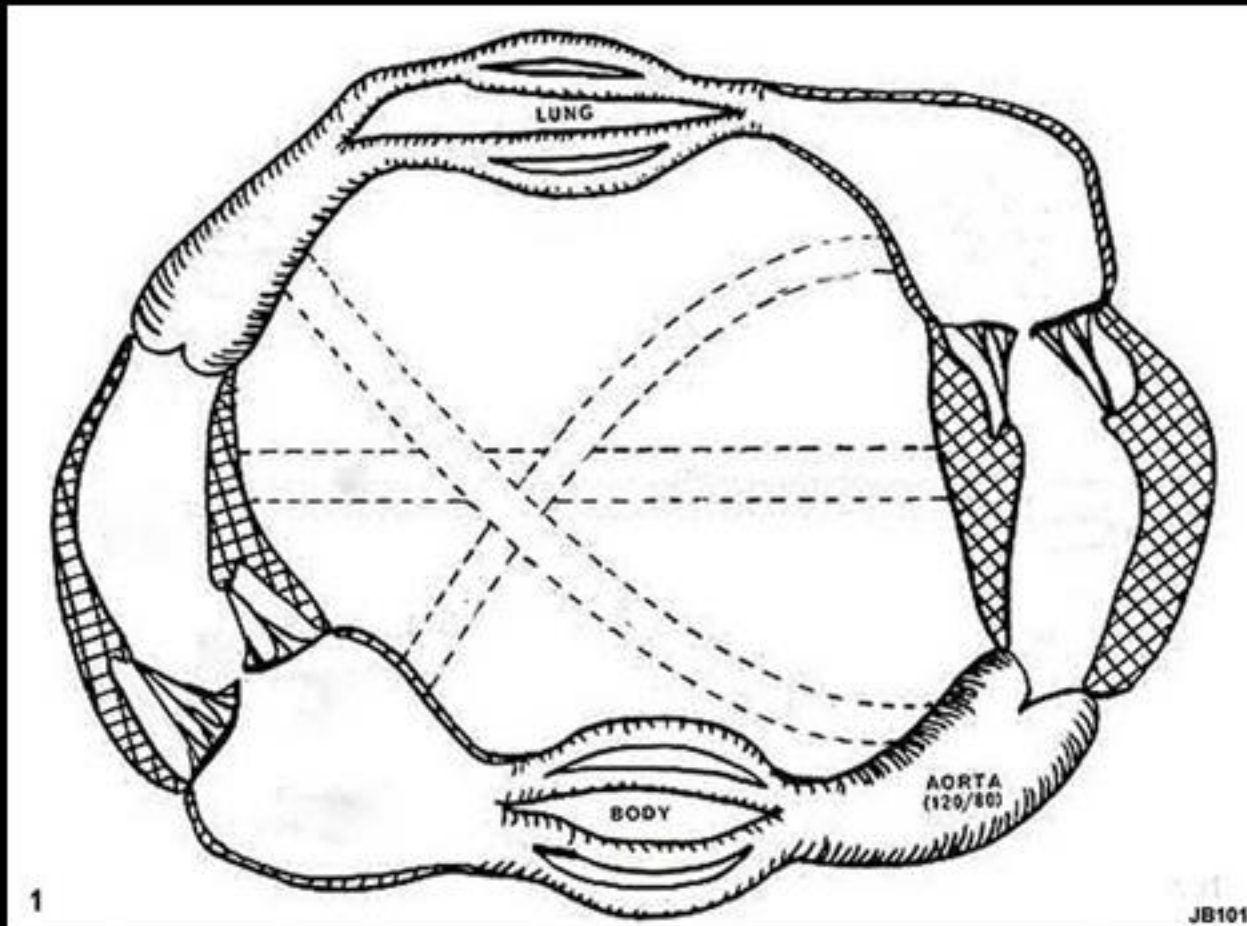
Pulmonary Vasculature



Hypovolemia



Blood Flow

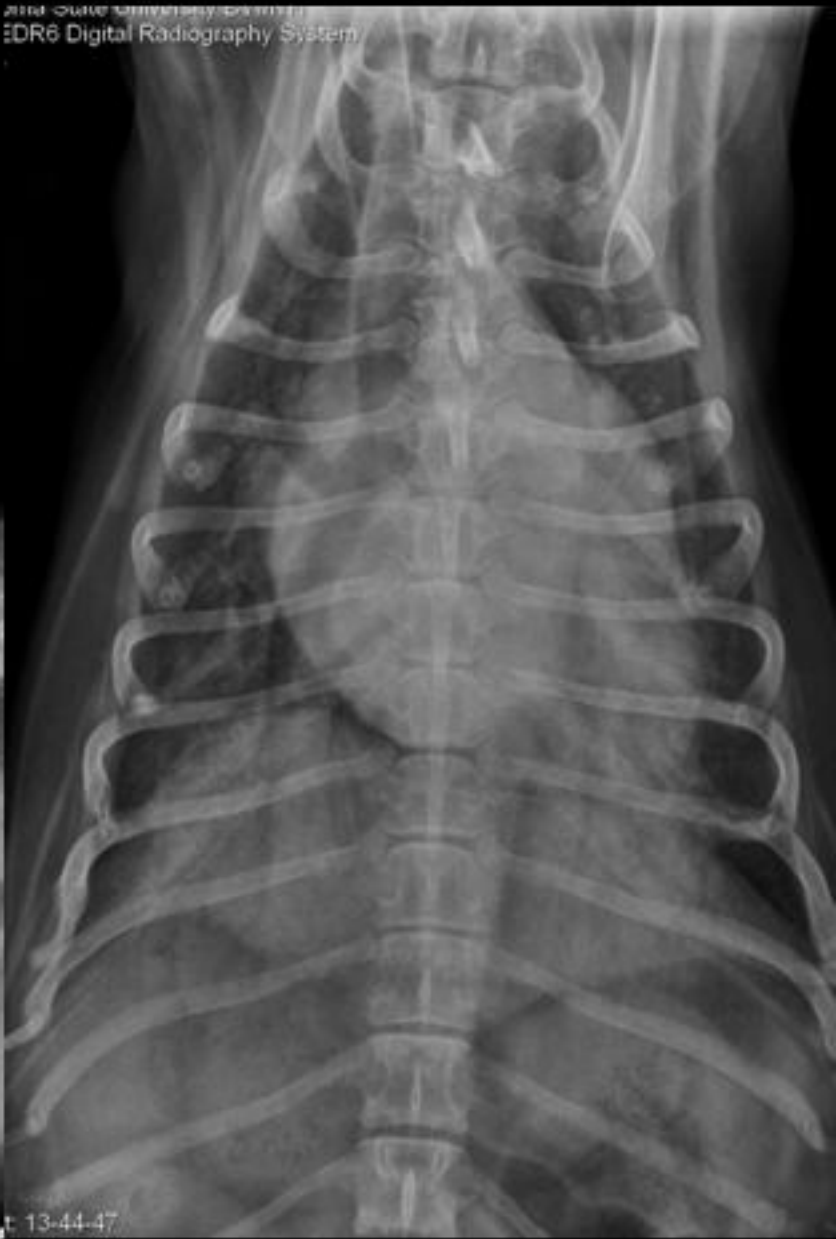
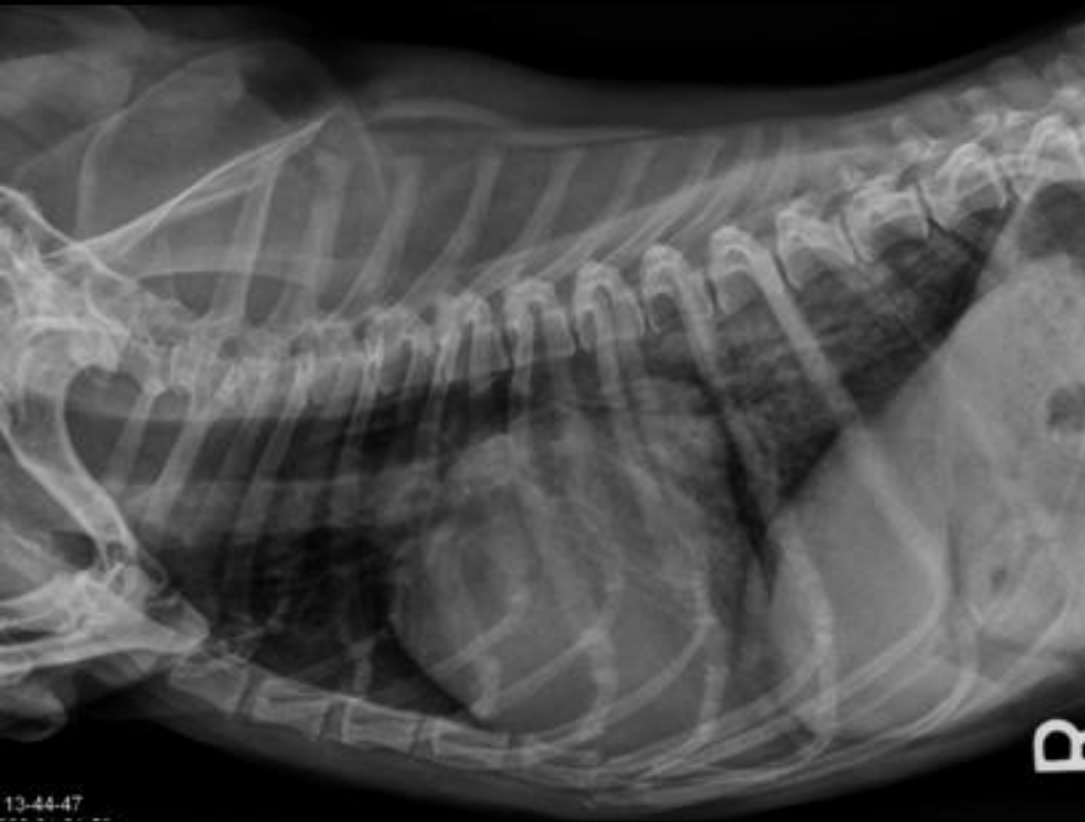
Left-sided Heart Failure-

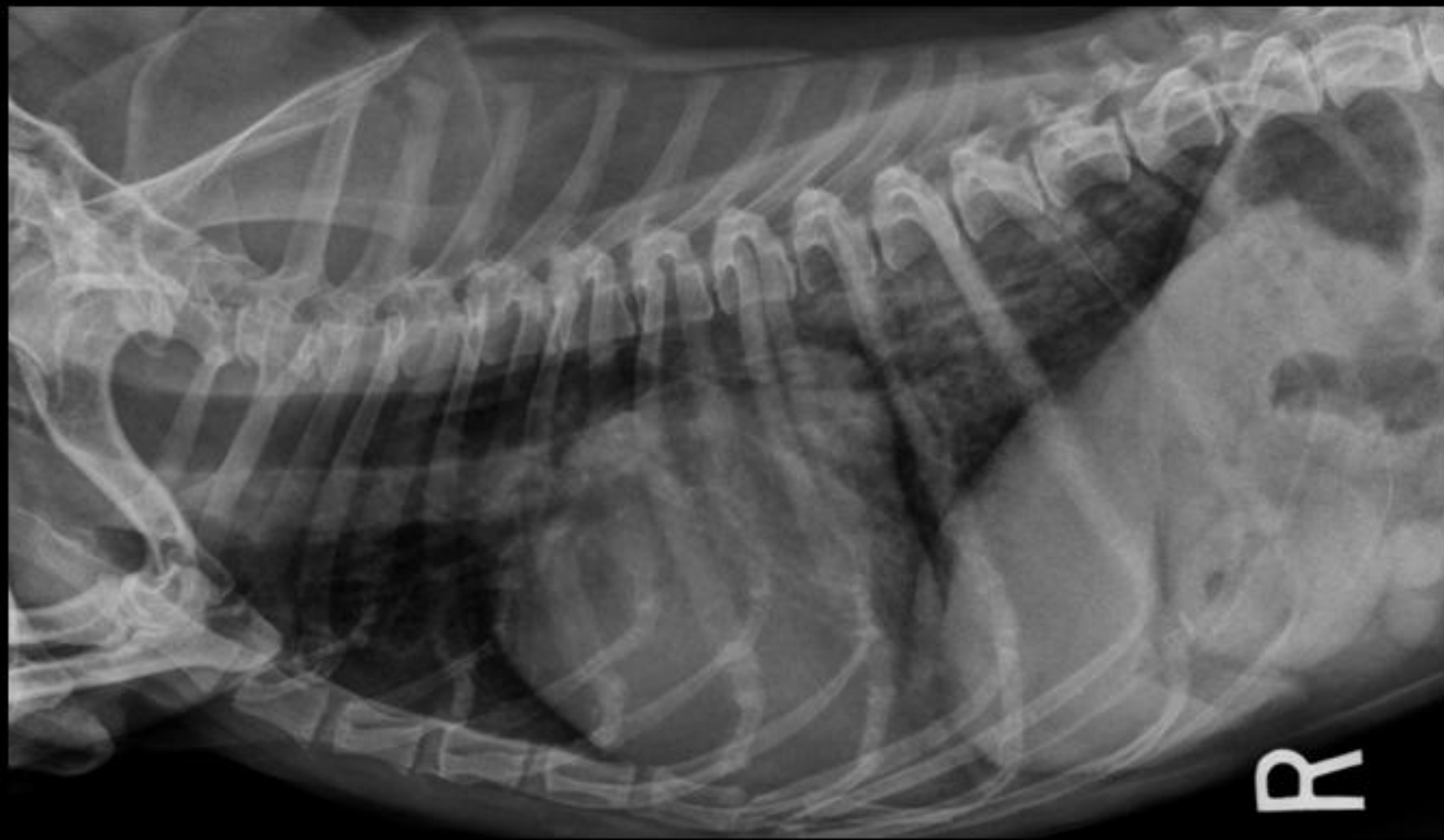
- ▣ Left Atrial Enlargement
- ▣ Left Ventricular Enlargement
- ▣ Pulmonary Venous Congestion
- ▣ Cardiogenic Pulmonary Edema
 - Caudodorsal, Perihilar
 - ▣ Except DCM (canine) and cats
- ▣ Pleural Effusion (only in cats)

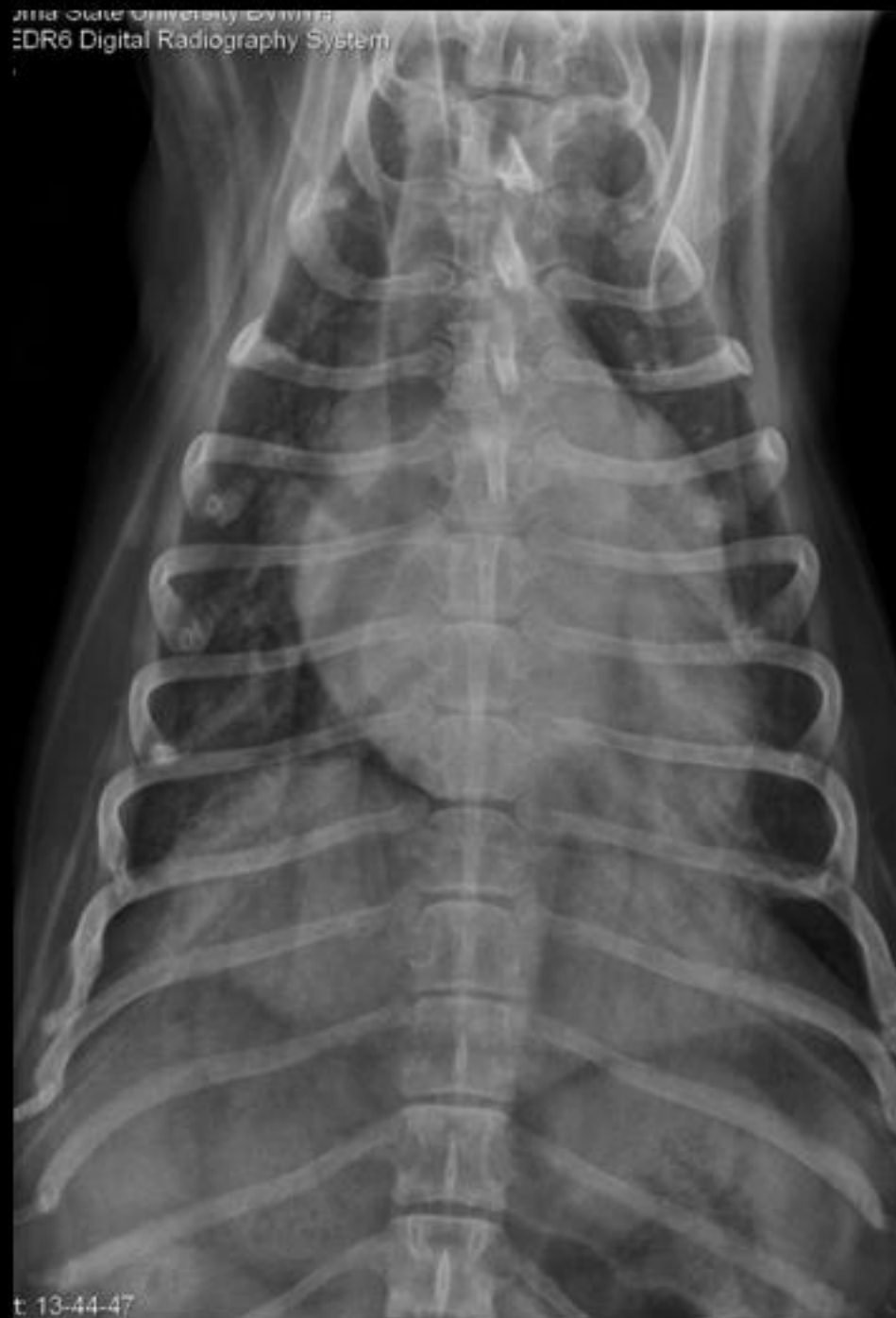Right-sided Heart Failure

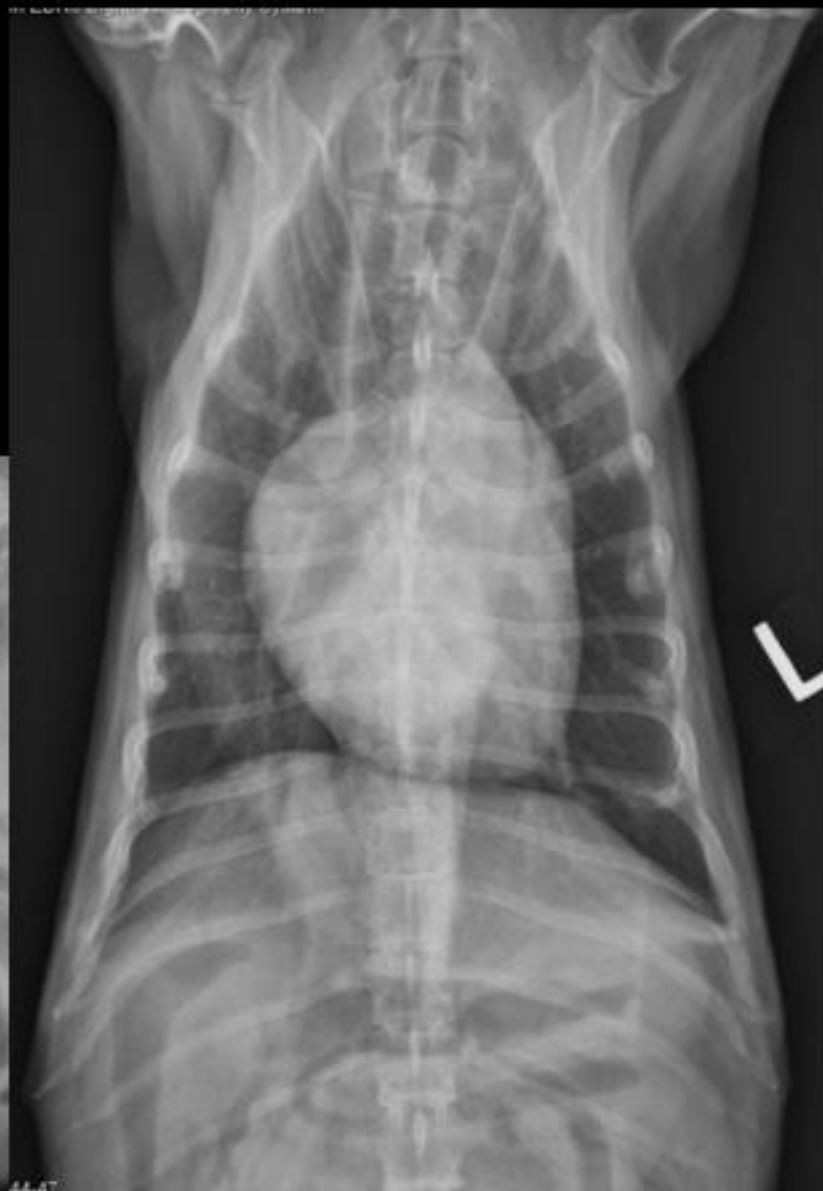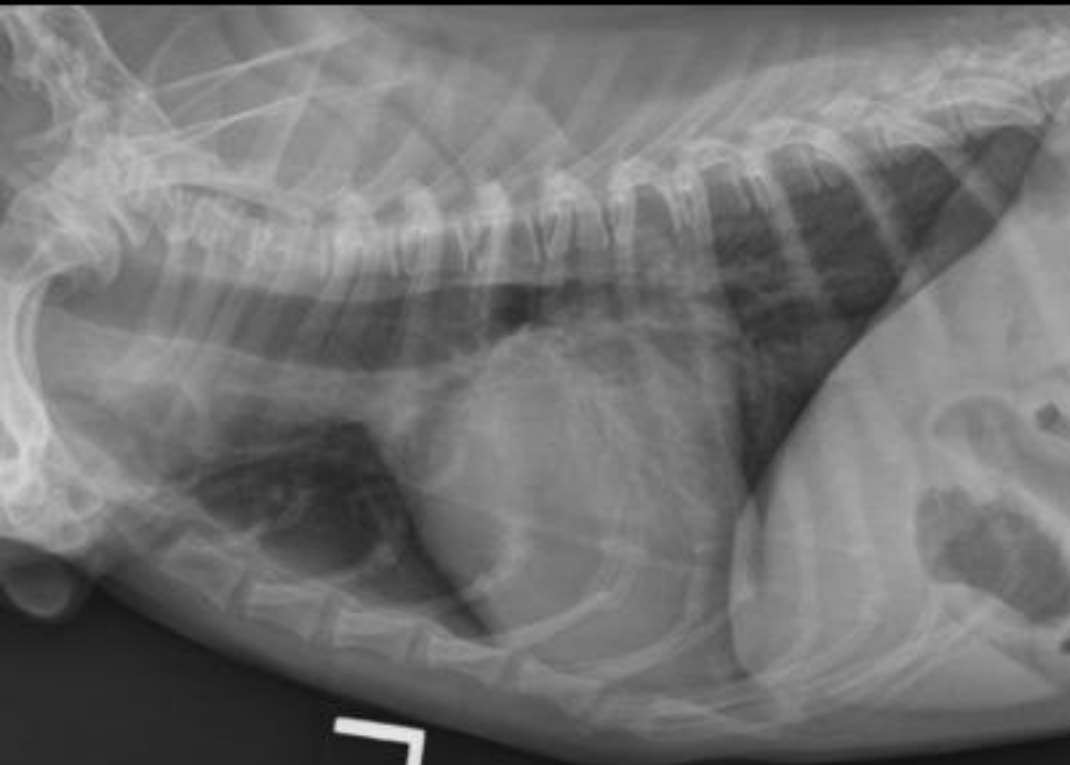- ▣ Right Sided Cardiomegaly
- ▣ Peritoneal Effusion (Ascites)
- ▣ Pleural Effusion
- ▣ Hepatic Congestion (Hepatomegaly)
- ▣ Enlarged Caudal Vena Cava

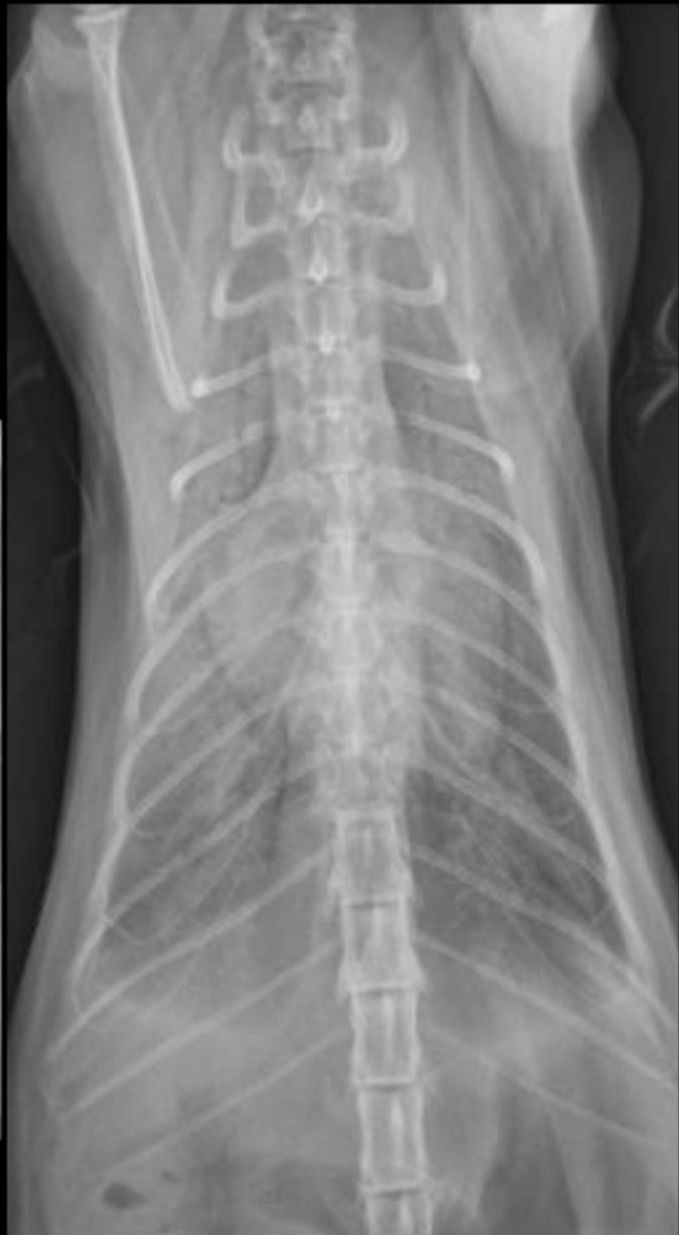
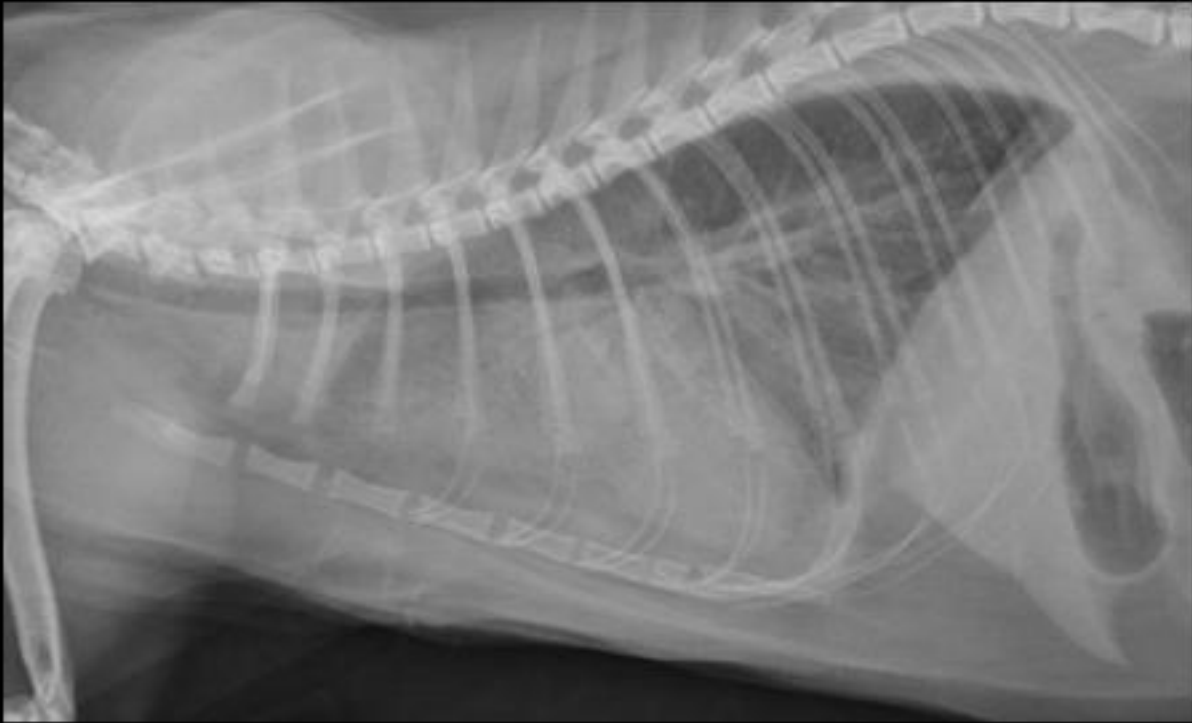
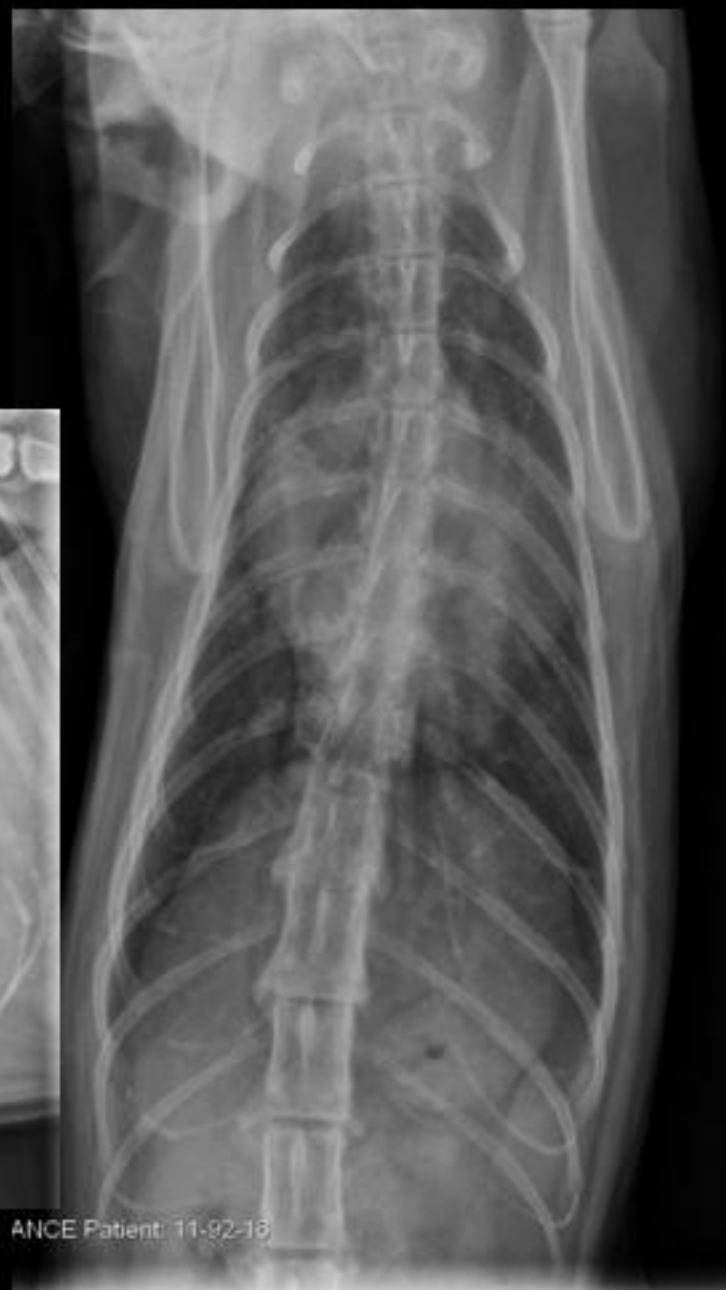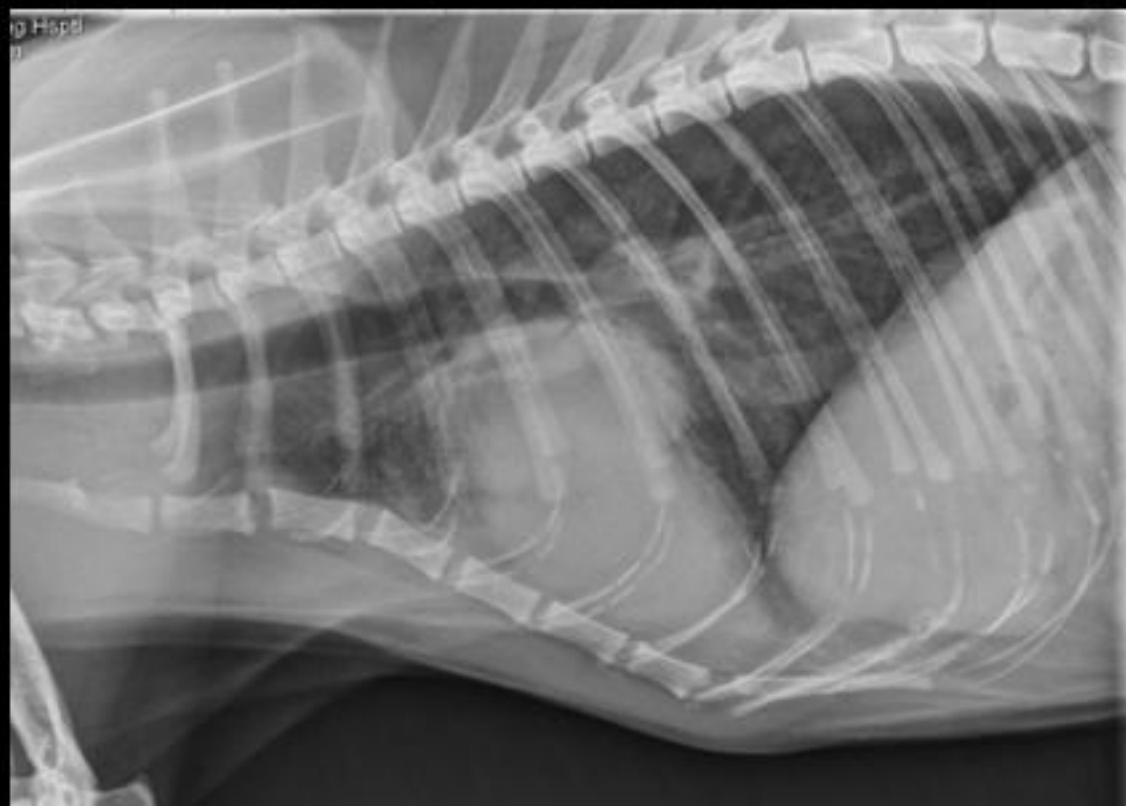
R 13-44-47











ANCE Patient: 11-92-16

